



Successful Management of Repeat Breeder Marwari Mare Due to Post Breeding Endometritis

Tarun Sutaria*, Ravji Chaudhari, Prajwalita Sutaria and Chandrakant Chaudhari

Department of Gynaecology & Obstetrics, Kamdhenu University, Sardarkrushinagar, Gujarat

ABSTRACT

An 11-year-old Marwari mare with a history of repeated unsuccessful conception despite normal cyclicity over three years was presented. Transrectal ultrasound revealed large follicles on the left ovary, uterine edema, and intrauterine fluid. Endometrial cytology and antibiotic sensitivity tests yielded negative results. The mare received treatment with Oxytocin, Gentamicin, and Tolfenamic Acid during estrus, along with GnRH post-breeding. Close monitoring during pre- and post-breeding led to a successful pregnancy, illustrating that appropriate evaluations and treatments can address post-breeding endometritis in repeat breeders.

Keywords: Marwari Mare, Post-breeding endometritis, Repeat Breeding, Ultrasonography

How To Cite: Sutaria, T., Chaudhari, R., Sutaria, P., & Chaudhari, C. (2024). Successful management of repeat breeder Marwari mare due to post breeding endometritis.

The Indian Journal of Animal Reproduction, 45(2), 119-125, 10.48165/ijar.2024.45.02.26

INTRODUCTION

Mares are seasonally polyestrous, showing increased oestrous activity during longer daylight periods, with a variable number of cycles per year. A mare that fails to conceive and remains empty during the breeding season is referred to as a repeat breeder or barren mare. Reasons for failure to conceive may include clinical/subclinical/post-breeding endometritis and improper breeding timing. The diagnostic approach for such mares involves a detailed reproductive history, clinical examination (including trans-rectal palpation and ultrasonography of the reproductive tract), and laboratory tests such as endometrial cytology and uterine swab culture for bacteriology, as well as biopsy (LeBlanc and Causey, 2009;

Buczkowska *et al.*, 2014). Due to its noninvasive nature, ultrasound allows for frequent serial examinations to evaluate regular cyclic morphological and pathological changes within the uterine endometrium and the presence of fluid inside the uterine lumen. Intrauterine fluid (IUF) serves as an indicator of endometritis during the diestrus period (Adams *et al.*, 1987). The scoring system for detecting endometrial oedema through transrectal ultrasonography helps predict ovulation time in normal mares and identifies mares in need of post-breeding therapies. (Samper, 1997). Bacteria, sperm, and inflammatory by-products are typically eliminated from the uterus within 24-48 hours; 10-15% of mares fail to do so, leading to the establishment and persistence of infection and inflammation, which negatively impacts fertility (Zent *et al.*, 1998). Mares with

*Corresponding author.

E-mail address: tarun.vets@gmail.com (Tarun Sutaria)

Received 24.06.2024; Accepted 26.11.2024

Copyright @ The Indian Society for Study of Animal Reproduction

endometritis are carefully examined and diagnosed using ultrasonography and endometrial cytology (LeBlanc and Causey, 2009). The therapeutic approach involves identifying and neutralizing infectious agents and correcting underlying predisposing conditions to prepare the endometrium for embryo descent, typically occurring about 6 days after mating (LeBlanc and Causey, 2009). The specific management depends on the etiological diagnosis.

A case study involving a repeat breeder Marwari mare was investigated and successfully managed, as described as short communication in the provided text.

CASE HISTORY AND OBSERVATIONS

A pluriparous eleven-year-old Marwari mare was presented to clinics with a prime complaint of failed conception after repeated coverings by the normal fertile stallion during previous breeding seasons for three years. On general examination, the mare was active, alert, and healthy with zero caslick’s index (Fig. 1) and a shiny body coat. The trans-rectal manual palpation and ultrasonography, as well as endometrial cytology and antibiotic sensitivity test, were performed at each mare’s clinical presentation.



Fig. 1: Measuring the vulvar angle of inclination to assess the Caslicks index

On the sixth of September 2021, the fourth day of estrus, the mare presented for the first time to clinics and was exhibiting normal estrus behaviour. The uterus was thick, heavy and edematous, with both ovaries being large and

Table 1: Ultrasonographic findings of Marwari mare on each clinical presentation.

Clinical Presentation and Examination Time	Ovarian Structure Size (cm)		UE Grade & IUF
	Left Ovary (cm)	Right Ovary (cm)	
6 th Sep-2021	DF-3.72	SF-3.34	5 & >1cm
21 st Oct-2021	DF-4.20	SF-2.11	2 & >1cm
22 nd Feb-2022	DF-3.28	SF-2.64	5 & <1cm
(Pre-Breeding)	SF-2.95		
25 th Feb-2022	CLH	AF-2.23	2 & No IUF
(2 days Post-Breeding)	SF-3.70		
28 th Feb-2022	1 Primary CL	AF-2.22cm	1 & <0.5cm
(5 days Post-Breeding)	and Luteinized SF		
5 th April-2022	CL- 1 Primary and 1 Secondary	CL- 1 Secondary	1 in uterine horn with presence of embryo in right horn
(Pregnancy, 41days Post-Breeding)	F- 4-5 in Nos, <2cm	F- 6-7 in Nos, <2cm	

DF-Dominant Follicle; SF-Subordinate Follicle; CLH-Corpus luteum Haemorrhagicum, CL-Corpus luteum; LF-Luteinized Follicle; AF-Atretic Follicle; F-Follicle; Nos-Number; UE-Uterine Edema; IUF-Intra uterine fluid

soft in consistency on per-rectal palpation. The trans-rectal ultrasound revealed the presence of large follicles on both left ovary (LO) and right ovary (RO); grade 5 uterine oedema (UE, Samper, 1997) and >1cm intrauterine fluid (IUF) (Fig. 2 & Table 1).




Fig. 2: The sequential ultrasonograms of reproductive tract to assess the changes in ovaries, uterine horns and body at each examinations

The endometrial cytology (EC, Field Stain) and bacteriology were negative (Fig. 3). Considering these findings, subsequent serial follicular and uterine examinations were required. However, the owner did not come for re-examination and was telephonically informed about covering the mare in the same estrus. The mare was presented on the twenty-first of October

2021 for a pregnancy diagnosis. The per-rectal examination revealed flaccid, non-gravid genitalia with a larger soft LO than RO. During trans-rectal ultrasound scanning, LO had a large dominant follicle, and RO had small-sized follicles, grade 2 UE and >1cm IUF (Fig. 2 & Table 1). The EC and bacteriology were also negative this time (Fig. 3).

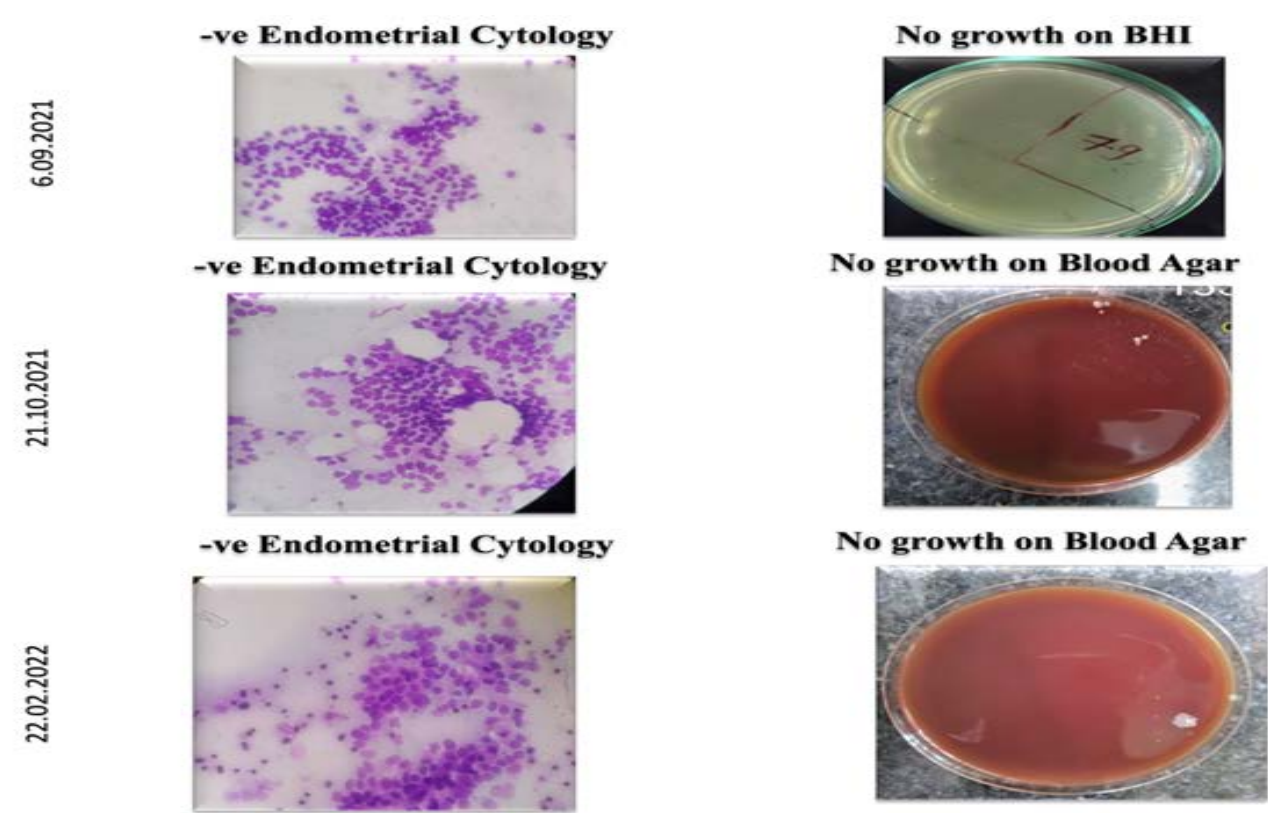


Fig. 3 : The pre-breeding endometrial cytology and bacteriology of mare

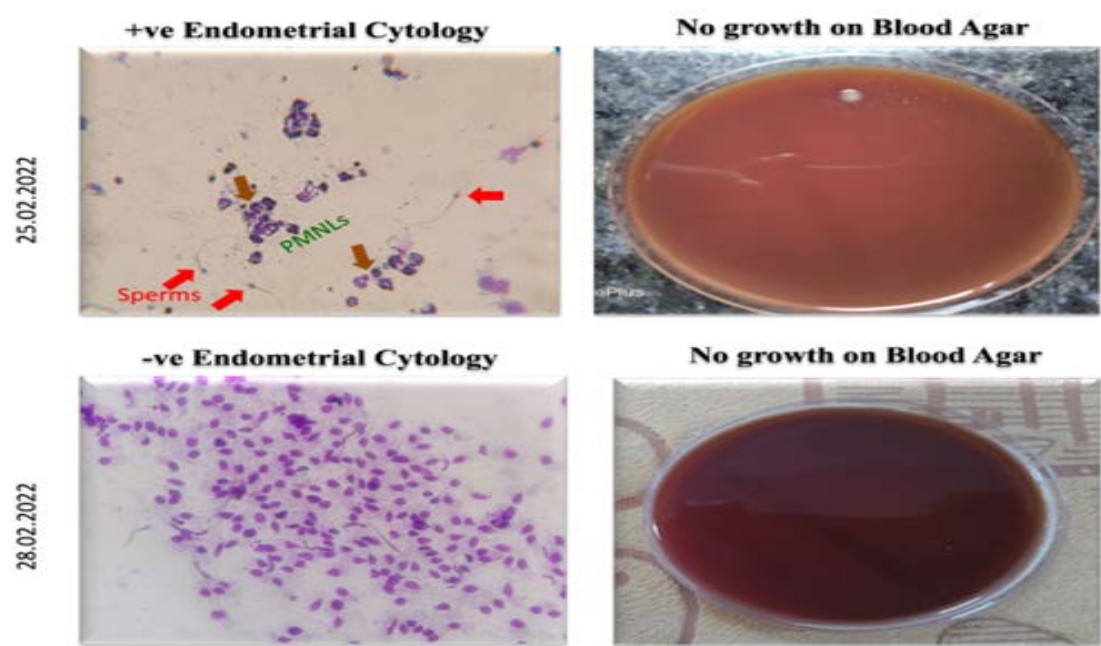


Fig.4 :The post-breeding endometrial cytology and bacteriology of mare.

TREATMENT AND DISCUSSION

Based on the examination, the mare was injected with an ovulation-inducing agent (hCG, Chorulon, 3000IU, i/v) and advised to cover in the morning on the twenty-second of October 2021 and post-breeding examination on the twenty-third of October 2021. Nevertheless, this time, the owner also did not come for a post-breeding examination. After that, the mare was brought on the twenty-second of February 2022 for pregnancy confirmation as the mare had not exhibited estrus for nearly four months. On per rectal examination, a symmetrical flaccid but heavy edematous uterus and large-sized ovaries were palpated. Ultrasonographically, two dominant follicles (DF) on LO and one subordinate follicle (SF) on RO were present (Fig. 2 & Table 1). The UE was grade 5 with <1cm IUF, EC and bacteriology were also negative (Fig. 3). The mare was advised to live cover in the evening of 23rd Feb-2022 and post-breeding examination. Luckily, the mare was presented for post-breeding examination on the twenty-fifth of February 2022. The post-breeding examination confirmed the ovulation and presence of corpus luteum haemorrhagica (CLH) with slight residue of follicular fluid (Fig. 2). The SF on LO increased in size from 2.95cm to 3.70cm, whereas SF on RO was atrophied and reduced in size from 2.64cm to 2.23cm. The UE was reduced to grade 2 from 5, and IUF was absent (Table 1). The post-breeding EC revealed the presence of neutrophils (+ve EC) due to post-breeding inflammation and spermatozoa, but bacteriology was negative (Fig. 4).

The post-breeding intrauterine infusion of diluted antibiotic (5ml Gentamicin+ 45ml Distilled water) and Inje. Oxytocin (10 IU, i/m, BID) along with oral anti-inflammatory drugs (Tolfenamic Acid, Bol. Maxxtol for five days, Intas Pharmaceuticals Ltd.) was advocated. The Buserelin acetate (Receptal, 10 ml) was injected intra-muscularly to strengthen newly formed CLH and luteinization of SFs. On the fifth day post-breeding, 28th Feb-2022, trans-rectally tonic and comparatively lighter uterus was evident with smaller ovaries. On USG, we found functional corpus luteum and luteinized SF on LO, 2.2cm follicle on RO and <0.5cm IUF in the right horn with grade 1 UE (Fig. 2). The EC revealed the presence of spermatozoa and was negative for neutrophils and bacteriology (Fig. 4). Again, intra-uterine treatment with Gentamicin (5ml) + Distilled water (45 ml) was performed, followed by oxytocin (10 IU, i/m

BID) for easy uterine clearance. The owner was advised to bring the mare for pregnancy diagnosis after 25 days.

The mare did not exhibit oestrus until presented for pregnancy diagnosis on the fifth of April 2022, i.e., 41 days since breeding. The uterus was asymmetrical, with an enlarged right horn on per-rectal palpation. The trans-rectal ultrasonography revealed the hypoechoic endometrial cups on the dorsal uterine wall with a hyperechoic embryo in the center of the embryonic vesicle filled with anechoic clear fetal fluid (Fig. 2). The uterine enlargement was 6.87cm in size at the point of the embryo. The LO had two active corpus luteum: primary CL formed from ovulation and another secondary CL due to complete luteinization of growing subordinate follicle (SF), and small multiple follicles (4-5 in Nos, <2cm) were also present. The RO also had a secondary CL and multiple follicles (6-7 in Nos, <2cm). The serum samples were also collected at pre- and post-breeding as well as at the time of pregnancy diagnosis. The serum biochemistry of the mare revealed all the parameters within the standard limit (Table 2), indicating the mare's normal healthy state. The mare foaled normally without any assistance, and the beautiful filly was born on the twenty-sixth of January, 2023. Again, the mare was covered on the twentieth of May 2023, and pregnancy was established successfully without any complications like earlier; she will foal soon in 2024.

Mares presented with the complaint of failure of conception should be serially ultrasonographically examined during estrus (pre-breeding) and one to two days post-breeding to identify uterine oedema, ovulation, and intrauterine fluid. The primary causes of infertility in mares include endometritis and improper breeding timing. Subfertility in problem mares is often linked to subclinical endometritis and post-breeding endometritis. The mare in question exhibited endometritis induced by mating, which was effectively treated with ecbolics, antibiotics, and anti-inflammatory therapy. In the present case, perineal confirmation was normal, and aerobic bacterial culture and cytology were negative. However, the uterus exhibited hyper edema with the presence of intrauterine fluid. Old, pluriparous mares may retain uterine oedema or exhibit an increasing degree of uterine oedema only after ovulation because of persistent mating-induced endometritis, lymphatic lacunae, or vascular degeneration. These mares may require repeated administration of ecbolics or immunomodulators (LeBlanc and Causey, 2009). Mares with hyper edema very often have either poor perineal conformation, predisposing them to aspirate air, or they have clinical or subclinical endometritis (Samper, 1997). Mares that exhibit visible intrauterine fluid (IUF) and those with even small amounts of IUF (<0.5 cm) or echogenic lines in

Table 2: Pre- & post breeding serum biochemistry of mare.

Parameters	Normal value	Pre-Breeding	Post-Breeding		
		22 nd Feb-2022	25 th Feb-2022 (2 Days)	28 th Feb-2022 (5 Days)	5 th April-2022 (Pregnancy 41 Days)
Total Protein	5.7 – 7.7 g/dL	7.30	7.20	7.30	7.40
Albumin	3.0 – 3.7 g/dL	4.50	4.20	4.10	4.10
Glucose	71 – 113 mg/dL	133.00	70.00	79.00	77.00
Urea	11 – 28 mg/dL	30.99	38.63	17.23	31.72
Triglycerides	14 – 77 mg/dL	44.121	119.39	124.88	51.790
AST(GOT)	199-374 U/L	297.90	278.70	263.00	196.9
Calcium	10.9 – 12.8 mg/dL	11.50	11.30	10.70	11.60
Inorganic Phosphorous	2.1 – 4.2 mg/dL	3.50	3.30	4.40	2.70

the uterine cavity are at risk of developing endometritis after mating (Chiba *et al.*, 2019). However, McKinnon *et al.* (1988) proposed that a small amount of IUF (<3 mm) does not require treatment. IUF can be present during estrus in the absence of endometrial infection or inflammation (Knutti *et al.*, 2000). It is also known that the presence of more than 2 cm of uterine fluid during estrus is a predictor of susceptibility to post-mating endometritis (Brinsko *et al.*, 2003). The post-breeding uterus showed slight IUF and hyperechoic endometrium, and EC revealed the presence of neutrophils and spermatozoa, but bacteriology was negative in our case. Our primary objective is to combat endometrial inflammation by improving uterine clearance and preventing bacterial contamination.

The present mare, in this case, was bred based on per-rectal palpation and ultrasonographic findings, as described earlier (Samper, 1997). Generally, Mares are bred when they have a large follicle (>4 cm in diameter) and show behavioral signs of estrus, and ovulation is confirmed 12–48 hr after mating (Chiba *et al.*, 2019). Accurately determining the time of ovulation is essential to maximize the chances of conception (Samper, 1997). To ascertain ovulation human chorionic gonadotropin (hCG) or deslorelin (Ovuplant) implants are routinely used in mares (Samper, 1997). The ovulation in this mare was confirmed during post-breeding sequential examinations. Uterine oedema decreased, as the mare approaches ovulation and after ovulation, which is corroborated with Samper (1997).

Intrauterine antibiotic therapy is useful for achieving positive outcomes in treatment (Trundell, 2020). The uterine flushing after 4 hours post-breeding is also advocated in the treatment to avoid interference with conception (Brinsko *et al.*, 2003). Ecbolics are administered as described to eliminate the infused fluids (LeBlanc and Causey, 2009). The administration of oxytocin during estrus and 48 hours

post-breeding induces muscular uterine contractions lasting from 30 minutes to 1 hour, but due to its short half-life, oxytocin needs to be repeated to enhance treatment effectiveness. (Gutjahr *et al.*, 2000). Prostaglandin synthesis from endometrial inflammation is inhibited by NSAID (Wolf *et al.*, 2012); therefore, tolfenamic acid was included in the treatment approach.

CONCLUSION

By providing comprehensive treatment and continuous pre- and post-breeding monitoring, we were able to achieve a successful pregnancy in this Marwari mare, who was a repeat breeder suffering from breeding-induced endometritis.

CONFLICT OF INTEREST

Authors have no conflicts of interest.

ACKNOWLEDGEMENTS

Authors are thankful to the university authorities.

REFERENCES

Adams, G. P., Kastelic, J. P., Bergfelt, D. R. and Ginther, O. J. (1987). Effect of uterine inflammation and ultrasonically-detected uterine pathology on fertility in the mare. *J. Reprod. Fertil. Suppl.*, **35**: 445–454.

- Brinsko, S.P., Rigby, S.L., Varner, D.D., and Blanchard, T.L. (2003). A practical method for recognizing mares susceptible to post-breeding endometritis. *Proc. Annual Convention of the Am. Assoc. Equine Prac.* **49**: 363–365.
- Buczkowska, J., Kozdrowski, R., Nowak, M., Raś, A., Staroniewicz, Z. and Siemieniuch, M. (2014). Comparison of the biopsy and cytobrush techniques for diagnosis of subclinical endometritis in mares. *Reprod. Biol. Endocrinol.*, **12**: 27.
- Chiba, A., Ujiie, Y. and Aoki, T. (2019). Relationship between the presence of intrauterine fluid and cervical bacteria in heavy draft mares before and after mating. *J. Equine Sci.*, **30**(4): 75–79.
- Gutjahr, S., Paccamonti, D.L., Pycock, J.F., Taverne, M.A., Dieleman, S.J. and van der Weijden, G.C. (2000). Effect of dose and day of treatment on uterine response to oxytocin in mares. *Theriogenology*, **54**: 447–456
- Knutti, B., Pycock, J.F., Weijden, G.C. and Küpfer, U. (2000). The influence of early post-breeding uterine lavage on pregnancy rate in mares with intrauterine fluid accumulations after breeding. *Equine Vet. Educ.*, **12**: 267–270.
- LeBlanc, M.M. and Causey, R.C. (2009). Clinical and subclinical endometritis in the mare: both threats to fertility. *Reprod. Domest. Anim.*, **44**(3): 10–22
- McKinnon, A.O., Squires, E.L. and Shideler, R.K. (1988). Diagnostic ultrasonography of the mare's reproductive tract. *J. Equine Vet. Sci.*, **8**: 329–333.
- Samper, J. C. (1997). Ultrasonographic appearance and the pattern of uterine edema to time ovulation in mares. Reprinted in the IVIS website with the permission of the AAEP. AAEP PROCEEDINGS. Vol. 43 / 1997 Pp: 189–191. Proceedings of the Annual Convention of the AAEP 1997
- Trundell, A.D. (2020). Equine reproduction: seasonality, endometritis, and twinning in the mare. IntechOpen. <https://www.intechopen.com/chapters/72567>.
- Wolf, C.A., Maslchitzky, E., Gregory, R.M., Jobim, M.I. and Mattos, R.C. (2012). Effect of corticotherapy on proteomics of endometrial fluid from mares susceptible to persistent post-breeding endometritis. *Theriogenology*, **77**: 1351–1359.
- Zent, W.W., Troedsson, M.H.T. and Xue J.-L. (1998). Post breeding uterine fluid accumulation in a normal population of Thoroughbred mares: A field study; Proceedings of the 40th Annual Convention of the American Association of Equine Practitioners; Baltimore, MD, USA. 6 December 1998; Pp. 64–65.