

Gross Morphological study on Scapula of Mithun (*Bos frontalis*)

Malsawmkima^{1*}, Imtiwati², Laltlankimi³, Lalsangpuii⁴

ABSTRACT

The present study was conducted on scapula of adult mithun to study the gross morphological anatomy and record certain biometrical measurements. The bones were procured by simple natural maceration process. The scapula of mithun was found to be a flat triangular bone having three angles, three borders and two surfaces. The dorsal border was convex and the scapular spine was found to be thickened and roughened at the middle and then bend/curved forward below and ended distally as a pointed projection, acromion process. The rim of glenoid cavity was found to be roughly quadrilateral in outline and presented a wide and a narrow notch at the lateral and cranio-medial aspect of the glenoid cavity, respectively. The average maximum length and width of the scapula were found to be 35.87 ± 0.43 cm and 20.85 ± 0.75 cm, respectively.

Key words: Gross morphology, Mithun, Morphometry, Scapula.

Ind J Vet Sci and Biotech (2024); 10.48165/ijvsbt.20.4.32

INTRODUCTION

Mithun, an endangered ruminant species belonging to the family Bovidae, is considered to be a ceremonial ox and living wealth of the tribal people of Arunachal Pradesh, Manipur, Mizoram and Nagaland. This valuable semi-wild animal plays an important role in the socio-economic condition of the tribal people of North Eastern India. Though many references are available regarding scapula of cow and buffalo, but the literature on scapula of mithun is not available yet. Thus the present study was undertaken to provide baseline data which may be useful in identification of the animal in the field of research, forensic and vetero-legal case.

MATERIALS AND METHOD

The scapulae of four adult mithun were collected from post-mortem site in the premises of College of Veterinary Science and Animal Husbandry, Jalukie, Nagaland (India). The bones were procured by simple natural maceration process, and then they were cleaned with water and treated with bleaching powder solution and sun dried. The distinguished gross anatomical features and measurements were recorded on the different parts of scapula. The measurements were made with the help of measuring tape, meter scale, thread and digital Vernier callipers.

The parameters recorded were: (1) Length of scapula: Maximum length of scapula from the middle of the dorsal border to the middle of the rim of glenoid cavity, (2) Width of scapula: Maximum distance between cranial border and caudal border, (3) Spine: Full length, maximum height, maximum thickness, acromion process of the scapular spine, (4) Length of facies serrata cervicis and length of

¹Department of Veterinary Anatomy, College of Veterinary Sciences & Animal Husbandry, Jalukie, Peren, Nagaland-797110, Central Agricultural University, India

²Department of Livestock Production Management, College of Veterinary Sciences & Animal Husbandry, Jalukie, Peren, Nagaland-797110, Central Agricultural University, India

³Department of Veterinary Pathology, College of Veterinary Sciences & Animal Husbandry, Jalukie, Peren, Nagaland-797110, Central Agricultural University, India

⁴Department of Biochemistry, College of Veterinary Sciences & Animal Husbandry, Jalukie, Peren, Nagaland-797110, Central Agricultural University, India

Corresponding Author: Malsawmkima, Department of Veterinary Anatomy, College of Veterinary Sciences & Animal Husbandry, Jalukie, Peren, Nagaland-797110, Central Agricultural University, India. e-mail: somkimak@gmail.com.

How to cite this article: Malsawmkima, Imtiwati, Laltlankimi, & Lalsangpuii. (2024). Gross Morphological study on Scapula of Mithun (*Bos frontalis*). *Ind J Vet Sci and Biotech*. 20(4), 150-152.

Source of support: Nil

Conflict of interest: The author(s) declare(s) that there is no conflict of interest.

Submitted 01/02/2024 **Accepted** 19/04/2024 **Published** 10/07/2024

facies serrata thoracis, (5) Circumference of scapular neck, (6) Distance of tuber scapula from anterior margin of glenoid cavity, (7) Distance of nutrient foramen at caudal border from the caudal margin of glenoid cavity, and (8) Glenoid cavity: Maximum cavity depth in the centre, cranial-caudal transverse diameter, latero-medial transverse diameter and circumference of the glenoid cavity. The data was subjected to statistical analysis and presented as mean \pm SE (Snedecor and Cochran, 1994).

RESULT AND DISCUSSION

The scapula of mithun was found to be a flat triangular bone having three angles such as cranial angle, caudal angle and distal angle; three borders such as cranial border, caudal border and dorsal border; and two surfaces such as medial surface and lateral surface. The distal/glenoid angle, connected to rest of the scapula by the neck, was found to be composed of a glenoid cavity and tuber scapula (Fig. 1 & 2). The present observations were in agreement with Patel *et al.* (1991), Muhammad and Shahid (2000), Dyce *et al.* (2009), Liebich *et al.* (2009), Budras *et al.* (2011), and Chaurasia *et al.* (2020) in different bovine sub-family members. The average maximum length of scapula was 35.87 ± 0.43 cm and ranged from 34.00 to 37.00 cm and the average maximum width was 20.85 ± 0.75 cm with ranged from 18.00 to 23.00 cm (Table 1).

The cranial border of scapula was found to be thin, sharp and convex at the upper half but smooth and concave at the lower half. The caudal border was rounded, slightly concave and the thickest of the borders. The dorsal border was found to be convex, pitted and thick where the spine met the border and towards the two ends. The dorsal border formed cranial angle and caudal angle with the cranial border and caudal border, respectively (Fig. 1). The caudal angle was found to be slightly thicker than the cranial angle. The distal angle of scapula was thick and comprised of a glenoid cavity and tuber scapula. The rim of glenoid cavity was found to be roughly quadrilateral in outline (Fig. 3). This finding was in agreement with Chaurasia *et al.* (2020) in Sahiwal cattle. Tuber scapula was separated by a small distance from the cranial aspect of glenoid cavity (0.45 ± 0.05 cm), a small and smooth coracoid process was found to be situated at its medial aspect. A wide notch and a narrow notch were found to be present at the lateral and cranio-medial aspect of the glenoid rim, respectively (Fig. 3).

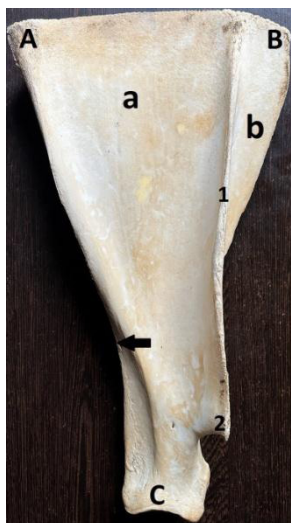

Fig. 1: Lateral surface of scapula of mithun showing (A) Caudal angle, (B) Cranial angle, (C) Distal angle, (a) Infraspinous fossa, (b) Supraspinous fossa, (1) Scapular spine, (2) Acromion process and black arrow showing Nutrient foramen.

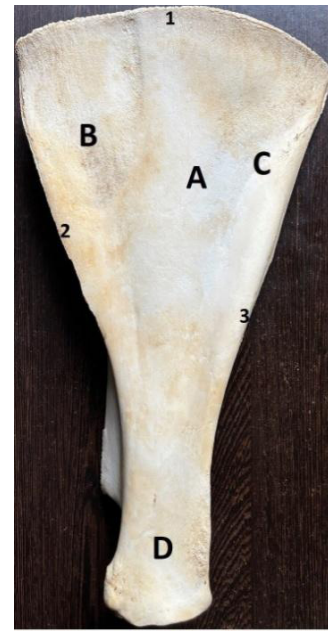


Fig. 2: Medial surface of scapula of mithun showing (A) Subscapular fossa, (B) Facies serrata cervicis, (C) Facies serrata thoracis, (D) Neck, (1) Dorsal border, (2) Cranial border, (3) Caudal border.

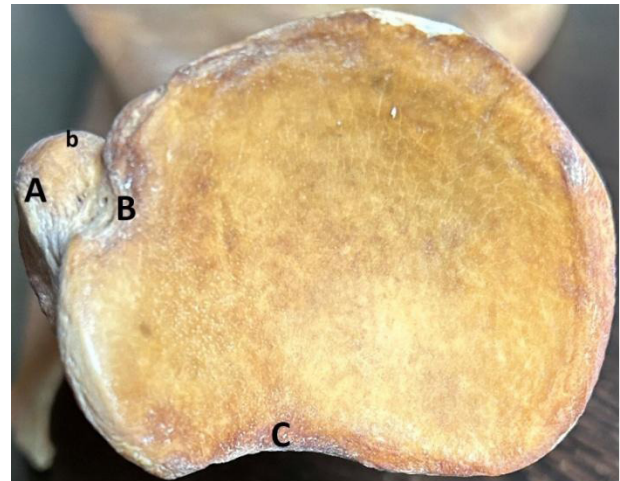

Fig. 3: Distal angle of scapula of mithun showing (A) Tuber scapula, (b) Coracoid process, (B) Narrow notch at cranio-medial aspect of glenoid cavity and (C) Wide notch at lateral aspect of glenoid cavity.

The nutrient foramen at the caudal border was situated 9.30 ± 0.46 cm away from the caudal margin of glenoid cavity (Fig. 1). The presence of foramen near the distal end of the spine was also observed. The depth of glenoid cavity at the center was 0.81 ± 0.07 cm and having a circumference of 17.07 ± 0.59 cm. The cranio-caudal and latero-medial transverse diameters were 5.42 ± 0.16 cm and 4.58 ± 0.15 cm, respectively. The circumference of scapular neck was found to be 13.05 ± 0.47 cm (Table 1).

The lateral surface of the scapula was divided by a prominent spine, scapular spine into two fossae, one large caudally present fossa, *i.e.*, infraspinous fossa and one small cranially present fossa, *i.e.*, supraspinous fossa. The height of

the spine was found to be increased distally and the thickness of the spine was found to be maximum at the middle. The spine terminated distally as a short pointed projection known as acromion process (Fig. 1). The costal/medial surface was found to be wide above and narrow below and presented a shallow subscapular fossa. The upper part of the surface presented a roughened triangular area, *i.e.*, facies serrata cervicis cranially and a rough line, *i.e.*, facies serrata thoracis caudally (Fig.2). The findings were in agreement with the previous reports (Muhammad and Shahid, 2000; Dyce *et al.*, 2009; Liebich *et al.*, 2009; Budras *et al.*, 2011; Chaurasia *et al.*, 2020) in different bovine sub-family members.

Table 1: Measurement of different parameters on scapula of mithun (*Bos frontalis*)

SI No.	Parameters	Mean \pm SE (cm)
1.	Total length of scapula	35.87 \pm 0.43
2.	Width of scapula	20.85 \pm 0.75
3.	Full length of scapular spine	31 \pm 0.61
4.	Maximum height of scapular spine	4.37 \pm 0.15
5.	Maximum thickness of scapular spine	0.71 \pm 0.08
6.	Length of Acromion process	0.93 \pm 0.17
7.	Length of Facies serrata cervicis	11.62 \pm 0.24
8.	Length of Facies serrata thoracis	10.06 \pm 0.35
9.	Circumference of scapular neck	13.05 \pm 0.47
10.	Distance of tuber scapula from anterior margin of glenoid cavity	0.45 \pm 0.05
11.	Distance of nutrient foramen from caudal margin of glenoid cavity	9.3 \pm 0.46
12.	Depth of glenoid cavity in the centre	0.81 \pm 0.07
13.	Cranial-caudal transverse diameter of glenoid cavity	5.42 \pm 0.16
14.	Latero-medial transverse diameter of glenoid cavity	4.58 \pm 0.15
15.	Circumference of the glenoid cavity	17.07 \pm 0.59

The average length of scapular spine was recorded as 31 \pm 0.61 cm and it ranged from 28.50 to 33.00 cm and that of acromion process was 0.93 \pm 0.17 cm and ranged from 0.40 to 1.50 cm. The average thickness of the scapular spine at the

middle was 0.71 \pm 0.08 cm and ranged from 0.50 to 1.00 cm. The spine of scapula was found to be running downward, thickened and roughened at the middle and bend forward below. The thickened and rough part at the middle of the spine was found to be neither bending nor curved over the infraspinous fossa (Fig. 1). The length of facies serrata cervicis and facies serrata thoracis were 11.62 \pm 0.24 cm and 10.06 \pm 0.35 cm, respectively. The length of facies serrata cervicis was found to be longer than that of facies serrata thoracis. This finding was in agreement with Chaurasia *et al.* (2020) in Sahiwal cattle.

In summary, the gross morphological anatomy and certain biometrical measurements of scapula of adult mithun recorded perhaps for the first time will provide baseline data which may be useful in identification of the animal in the field of research, forensic and vetero-legal case.

ACKNOWLEDGEMENT

The authors are thankful to the Vice-Chancellor, CAU and the Dean of the College for providing us whatever necessary materials for carrying out the study.

REFERENCES

- Budras, K.D., Habel, R.E., Muelling, C.K.W., & Greenough, P.R. (2011). *Bovine Anatomy: An Illustrated Text*. 2nd edn. (Vet Schlutersche) Manson Publishing Ltd.
- Chaurasia, D., Ingole, S.P., Deshmukh, S.K., & Nety, S. (2020). Gross Morphometrical study on scapula of Sahiwal cattle. *Veterinary Practitioner*, 21(1), 46-47.
- Dyce, K.M., Sack, W.O., & Wensing, C.J.G. (2009). *Textbook of Veterinary Anatomy*. 3rd edn. Elsevier, a division of Reed Elsevier, Pvt. Ltd. Noida, India.
- Liebich, H.G., Maierl, J., & Konig, H.E. (2009). *Veterinary Anatomy of Domestic Mammals*. Eds. Konig HE and Liebich HG. 4th edn. Schattauer Stuttgart, New York.
- Muhammad, F., & Shahid, R. (2000). Comparative gross anatomy of the appendicular skeleton of buffaloes and cows. *Pakistan Veterinary Journal*, 20(3), 159-160.
- Patel, K.B., Desai, M.C., & Pancharukhi, B.G. (1991). Age related gross changes in the bones of thoracic limb of buffalo (*Bubalus bubalis*). *Indian Journal of Veterinary Anatomy*, 3(1), 5-9.
- Snedecor, G.W., & Cochran, W.G. (1994). *Statistical Methods*. 8th edn. The Iowa State University Press, Amer, Iowa. USA.

