

# Clinical Management of Equine Piroplasmosis

Piyush G. Dodiya<sup>1\*</sup>, Jayesh S. Patel<sup>2</sup>, Vijay L. Parmar<sup>2</sup>, Vinay A. Kalariya<sup>3</sup>, Vivek K. Singh<sup>4</sup>

## ABSTRACT

Total 200 cases of horses presented at the Veterinary Clinical Complex of the College of Veterinary Science & AH, Junagadh were screened for equine piroplasmosis. Out of which, 9 (4.50%) were confirmed positive based on classical clinical signs and Giemsa-stained blood smears. Hematological examination was conducted in all equine piroplasmosis positive horses, which revealed significant decrease in RBCs, Hb, PCV, MCHC and thrombocytes, and no significant alteration in total and differential leukocyte count. The confirmed cases were successfully treated with buparvaquone @ 4 mg/kg deep intramuscular along with supportive therapy for 1 to 3 weeks.

**Keywords:** Equine piroplasmosis, Hemoglobinuria, Icterus, Puparvaquone, *Theileria equi*.

*Ind J Vet Sci and Biotech* (2022): 10.21887/ijvsbt.18.2.29

## INTRODUCTION

Equine piroplasmosis is an endemic tick-borne Hemoprotozoan disease of equines caused by intra-erythrocytic protozoa; *Babesia caballi* and *Babesia equi* (Russell *et al.*, 2005; Bhojani *et al.*, 2021). These parasites are widely distributed in the world, and the prevalence corresponds to the presence of the tick-vectors (Kumar and Kumar, 2007; Motloang *et al.*, 2008). The clinical picture of the disease in horses is variable and may be manifested by fever, oedema of the ventral abdomen, icterus and Hemoglobinuria. Generally, it is presumed that carriers are responsible for the propagation and maintenance of the infection (Constable *et al.*, 2017). The disease and its severity not only depend on the virulence of the causative agent, but also to a large extent on the degree of host susceptibility. The disease is more severe in those horses moved from tick-free areas to tick infested areas or in animals suffering from stress (Onyiche *et al.*, 2019). The diagnosis of acute babesiosis is mainly based on clinical findings and microscopic examination of 10% Giemsa-stained thin blood smears. However, expertise in piroplasm microscopy is required in unapparent carrier horses or chronic infections because parasitaemias are often extremely low and may otherwise be missed (Hodgson, 2002). Equine piroplasmosis affected horses can be therapeutically managed with anti-theilerial drug buparvaquone at 4–6 mg/kg b.wt. intravenously or intramuscularly along with supportive therapy (Salib *et al.*, 2013). Therefore, this study was planned to evaluate the clinical and therapeutic management of Equine Piroplasmosis in horses of Saurashtra region of Gujarat, state of India.

## MATERIALS AND METHODS

The study was conducted at the Department of Veterinary Medicine, College of Veterinary Science, Junagadh. Total 200 horses presented at VCC were screened for equine piroplasmosis, of which nine animals were found positive.

<sup>1</sup>Polytechnic in Animal Husbandry, College of Veterinary Science & Animal Husbandry, Junagadh-362001, Kamdhenu University, Gujarat, India.

<sup>2</sup>Department of Veterinary Medicine, College of Veterinary Science & Animal Husbandry, Junagadh-362001, Kamdhenu University, University, Gujarat, India.

<sup>3</sup>Department of Veterinary Pathology, College of Veterinary Science & Animal Husbandry, Junagadh-362001, Kamdhenu University, University, Gujarat, India.

<sup>4</sup>Department of Veterinary Physiology and Biochemistry, College of Veterinary Science & Animal Husbandry, Junagadh-362001, Kamdhenu University, University, Gujarat, India.

**Corresponding Author:** Piyush G. Dodiya, Polytechnic in Animal Husbandry, College of Veterinary Science & Animal Husbandry, Junagadh-362001, Kamdhenu University, Gujarat, India, e-mail: drpiyush.dodiya@gmail.com

**How to cite this article:** Dodiya, P.G., Patel, J.S., Parmar, V.L., Kalariya, V.A., & Singh, V.K. (2022). Clinical Management of Equine Piroplasmosis. *Ind J Vet Sci and Biotech*. 18(2), 129-131.

**Source of support:** Nil

**Conflict of interest:** None.

**Submitted:** 20/09/2021 **Accepted:** 17/12/2021 **Published:** 10/04/2022

All the positive horses were clinically examined for rectal temperature, heart rate, respiration rate, color of conjunctival mucous membrane, etc. Ten healthy horses which were negative for equine piroplasmosis served as healthy control group. About 5 ml of blood was collected from jugular vein of all 19 horses for detailed parasitological and Hematological investigations, viz., Hb, TEC, TLC, DLC, PCV and total platelets count by automatic Hematoanalyzer (Abacus Junior Vet.5, India). Diagnosis was confirmed by the detection of babesia in Giemsa-stained thin blood smears examined under oil immersion microscope.

All the nine piroplasmosis positive horses were therapeutically managed by administration of buparvaquone @ 4 mg/kg b.wt. deep intramuscularly daily for four days.

Supportive therapy included Flunixin meglumine @ 2.2 mg/kg as NSAID, Vitamin B1, B2 & B6 injection 15 mL i/v (Tribivet, Intas pharma) and Butaphosphan 15 mL i/v (Catosol, Bayer pharma) as general tonics for 5 days. The rehydration therapy included Dextrose normal saline two liters, Ringer's lactate two liters and Intalyte (Intas pharma) one liter intravenously. Plasma extender (Hemacel) 500 mL i/v and amino acids (Astymin-3) 300 mL i/v were also given in icteric horses consecutively for three days. Liver tonic (Livoferol liquid, Intervet pharma) 50 mL orally twice a day was given in all horses for 15 days to correct the anaemia and response was recorded.

The data on Hematological parameters were subjected to statistical analysis by the Student's 't' test, where  $p < 0.05$  was considered as statistically significant.

## RESULTS AND DISCUSSION

### Clinical Findings

The mean values of rectal temperature, heart rate and respiration rate of infected nine horses were  $102.73 \pm 0.42^\circ\text{F}$ ,  $48.67 \pm 2.23$  per minute and  $19.00 \pm 2.24$  per minute, respectively. Among nine piroplasmosis positive horses, in early-stage fever, pale conjunctiva (88.88%), anorexia (88.88%), and weakness were observed, while chronically infected horses showed signs of inappetence (88.88%), icterus, Hemoglobinuria (55.55%), progressive emaciation (66.66%), weakness, oedema of hind legs (66.66%), and dullness and depression. Similar clinical signs of equine piroplasmosis were also observed earlier by Chhabra *et al.* (2012), Short *et al.* (2012) and Chaudhary *et al.* (2014).

High temperature in equine piroplasmosis (EP) might be due to intra-erythrocytic parasitemia, which results into Hemolytic anaemia and Hemoglobinuria or coffee colored urine. Equine piroplasmosis is a tick-borne protozoal disease of horses, mules, donkeys, and zebras that is characterized by acute Hemolytic anaemia (Rothschild, 2013). Pale or icteric mucous membrane that represent a constant feature of the disease is largely due to hyperbilirubinemia from severe intravascular Hemolysis as a result of multiplication of the piroplasms inside red blood cells (Constable *et al.*, 2017). Jaundice occurs because of the increase in the indirect (un-conjugated) bilirubin, which is deposited in mucosal surfaces and elsewhere, imparting a yellow color to those tissues (Rothschild, 2013). Camacho *et al.* (2005) explained the weight loss in infected horses due to energy uptake by piroplasms in the form of adenosine tri-phosphate (ATP) and adenosine mono-phosphate (AMP) deprive the host (horse) of essential energy for normal anabolic processes, thus contributing to the loss of weight.

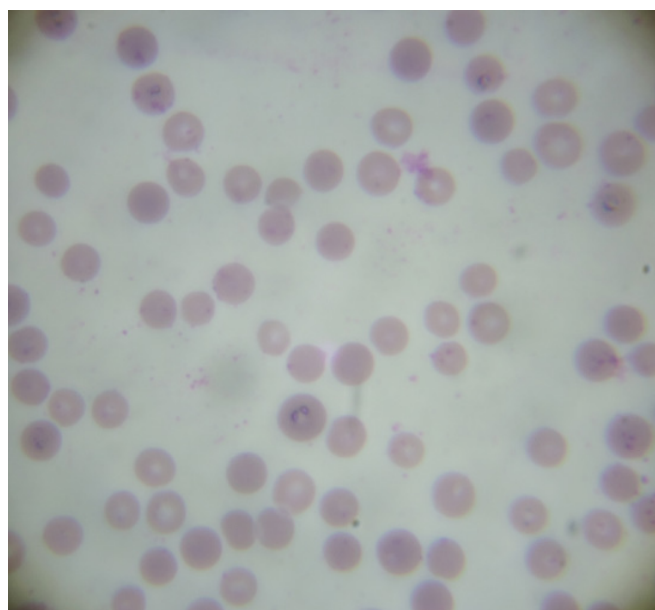
### Hematological Findings

Hematological analysis of infected horses depicted significant decrease in RBCs, Hb, PCV, MCHC and thrombocytes, with

increased WBCs, while no significant alteration in differential leukocytes and platelet counts was observed when compared with values of healthy horses (Table 1). Similar results were also recorded previously by Alsaad (2014) and Bhojani *et al.* (2021). Ambawat *et al.* (1999) mentioned that the alterations in erythrocyte membrane protein and lipid content and increase in plasma malondialdehyde observed during severe parasitemia suggest accumulation of oxidative ions resulting from lipid peroxidation that alters the erythrocytes' biochemical composition, leading to Hemolysis. Moreover, they added that thrombocytopenia may be a result of low-grade disseminated intravascular coagulopathies.

### Confirmatory Diagnosis

Out of 200 horses screened by Giemsa-stained thin blood smears, nine horses (4.50%) were found positive for equine piroplasmosis. Microscopic examination of Giemsa-stained smears of infected horses revealed intra-erythrocytic pyriform merozoites showing maltase cross (Fig. 1). Intra-erythrocytic maltase cross is considered as diagnostic



**Fig. 1:** Intra-erythrocytic, pyriform merozoites of *B. equi* showing maltase cross

**Table 1:** Hematological changes in equine piroplasmosis (EP) in comparison to healthy ones (Mean  $\pm$  SE)

Parameters	EP Positive (n=9)	Healthy (n=10)
Hb (g/dL)	10.82 $\pm$ 0.78*	12.61 $\pm$ 0.45
PCV (%)	32.63 $\pm$ 2.38*	36.80 $\pm$ 1.32
RBC ( $\times 10^6/\mu\text{L}$ )	6.53 $\pm$ 0.43*	8.10 $\pm$ 0.35
WBC ( $\times 10^3/\mu\text{L}$ )	12.85 $\pm$ 0.81*	9.80 $\pm$ 0.44
Lymphocytes (%)	38.15 $\pm$ 3.51	37.41 $\pm$ 1.81
Neutrophils (%)	61.00 $\pm$ 4.10	59.10 $\pm$ 1.83
Platelets ( $\times 10^6/\mu\text{L}$ )	1.63 $\pm$ 0.17	2.031 $\pm$ 0.155

\*P < 0.04 between groups.

feature of *B. equi* (OIE terrestrial manual, 2014; Bhojani *et al.*, 2021).

### Therapeutic Management

Buparvaquone is a second generation hydroxy naphthoquinone a specific therapy for Theileriosis and Babesiosis. All the nine horses treated by buparvaquone @ 4 mg/kg b.wt. i/m along with supportive (Flunixin meglumine; Vitamin B1, B2 & B6 injection, Butaphosphan for 5 days) and rehydration (Dextrose normal saline, Ringer's lactate and Intalyte) therapy, with Plasma expaner and amino acids in icteric for three days responded well. The liver tonic given orally twice a day for 15 days corrected anaemia in all horses.

Buparvaquone, a hydroxyquinone derivative has been investigated for the treatment of leishmaniasis, cryptosporidiosis and equine piroplasmosis and is recommended as gold standard for the treatment of theileriosis. Recent studies on *Babesia* have reported the development of resistance to Diminazene aceturate and documented toxic side effects in imidocarb dipropionate treated equines (Nugraha *et al.*, 2019).

### CONCLUSION

In the present study, all the horses successfully recovered from infection after above mentioned therapeutic management without any complications. Acute cases (2) were recovered within two weeks, while chronic cases (7) took more than three weeks for recovery after initiation of treatment.

### ACKNOWLEDGEMENT

The authors are thankful to the Principal and Dean and other staff members, College of Veterinary Science and AH, KU, Junagadh, Gujarat, India for providing necessary facilities to carry out this study.

### REFERENCES

- Alsaad, K.M. (2014). Evaluation of Hemogram, acute phase response, acid base balance and blood gas analysis in newborn foals infected with babesiosis. *Journal of Animal and Plant Science*, 24, 738-742.
- Ambawat, H.K., Malhotra, D.V., Kumar, S., & Dhar, S. (1999). Erythrocyte associated hemato-biochemical changes in *Babesia equi* infection experimentally produced in donkeys. *Veterinary Parasitology*, 85, 319-324.
- Bhojani, R.J., Chahar, A., Dedar, R.K., & Kachhawa, J.P. (2021). Hemato-biochemical studies on *Theileria Equi* infection in seropositive horses. *The Indian Journal of Veterinary Science & Biotechnology*, 17(2), 92-94.
- Camacho, A.T., Guitian F.J., Pallas, E., Gestal, J.J., Olmeda, A.S., Habela, M.A., Telford, S.R., & Spielman, A. (2005). *Theileria (Babesia) equi* and *Babesia caballi* infections in horses in Galicia, Spain. *Tropical Animal Health and Production*, 37, 293-302.
- Chaudhry, M., Rashid, H.B., Khan, M.S., & Pervez, K. (2014). Comparative efficacy of various drugs used against naturally infected horses with babesiosis. *Science International*, 26(1), 267-271.
- Chhabra, S., Ranjan, R., Uppal, S.K., & Singla, L.D. (2012). Transplacental transmission of *Babesia equi (Theileria equi)* from carrier mares to foals. *Journal of Parasitic Diseases*, 36(1), 31-33.
- Constable, P.D., Hinchcliff, K.W., Done, S.H., & Grunberg, W. (2017). *Veterinary Medicine*. A text book of the diseases of cattle, sheep, goats and horses. 11<sup>th</sup> ed. Elsevier, pp. 811-814.
- Hodgson, J. (2002). *Equine Exotic Diseases: A Manual for Horse Owners*. RIRDC Publication No. 02/054, Printed by Union Offset, Canberra, pp. 47-49.
- Kumar, S., & Kumar, R. (2007). Diagnosis of *Babesia equi* infection: An update on the methods available. *CAB Review on Perspective Agriculture Veterinary Science Nutrition and Natural Resources*, 2, 1-14.
- Motloang, M.Y., Thekiso, O.M.M., Alhassan, A., *et al.* (2008). Prevalence of *Theileria equi* and *Babesia caballi* infections in horses belonging to resource poor farmers in the north-eastern Free State Province, South Africa. *Onderstepoort Journal of Veterinary Research*, 75, 141-146.
- Nugraha, A.B., Tuvshintulga, B., Guswanto, A., Tayebwa, D.S., *et al.* (2019). Screening the medicine for Malaria venture pathogen box against piroplasm parasites. *International Journal of Parasitology*, 10, 84-90.
- OIE Terrestrial Manual (2014). Equine piroplasmosis. Chapter 2.5.8.
- Onyiche, T.E., Sukanuma, K., Igarashi, I., Yokoyama, N., Xuan, X., & Thekiso, O. (2019). A Review on equine piroplasmosis: Epidemiology, vector ecology, risk factors, host immunity, diagnosis and control. *International Journal of Environmental Research and Public Health*, 16, 1-23.
- Rothschild, C.M. (2013). Equine piroplasmosis. *Journal of Equine Veterinary Sciences*, 33, 497-508.
- Russell, Z.E., Holly, M., Bruce, E.L., & Latimer, A. (2005). Equine babesiosis: A review. Athens, GA: College of Veterinary Medicine, University of Georgia. p. 3062-7388.
- Salib, F.A., Youssef, R.R., Rizk, L.G., & Said, S.F. (2013). Epidemiology, diagnosis and therapy of *Theileria equi* infection in Giza, Egypt. *Veterinary World*, 6(2), 76-82.
- Short, M.A., Clark, C.K., Harvey, J.W., Wenzlow, N., *et al.* (2012). Outbreak of equine piroplasmosis in Florida. *American Veterinary Medical Association*, 240(5), 588-595.