

RESEARCH ARTICLE

Gross and Biometric Studies on Pelvic Bone of the Emu (*Dromaius novaehollandiae*)

Ishita Barvalia¹ and KM Panchal²

ABSTRACT

The bones of pelvic girdle of emu were studied. The two large os-coxae were less widely separated. No symphysis was found between two pelvic bones. The fossa renalis was absent. The short pre-acetabular part was in the form of a rough quadrilateral plate, while the long post-acetabular part was in the form of an elongated triangle. The acetabulum was a deep cavity and perforated. The large ante-trochanter was found on caudodorsal part of the acetabulum. The foramen ischiadicum was in the form of a long ilio-ischiatic incisure. Pubis was a thin rod-like bone directed caudally parallel to the ischium. The large ischio-pubic incisure was divided incompletely into oval obturator foramen cranially and elongated slit caudally. The gross anatomy of os coxae of emu bird and its biometry have been described in detail.

Keywords: Avian anatomy, Emu, Gross structure and biometry, Os-coxae, Pelvic limb.

Ind J of Vet Sci and Biotech (2019): 10.21887/ijvsbt.14.4.6

INTRODUCTION

The Emu (*Dromaius novaehollandiae*), a large ratite and flightless bird, is an omnivorous species with cursorial lifestyle and is the second largest bird in height, after the Ostrich (Eastman, 2003). In Emu legs are very long and provide for locomotion, defense and access to food (Brett and Hopkins, 1991). Their ability to run at high speed is due to their highly specialized pelvic limb musculature. The name “*Dromaius novaehollandiae*” in Latin means “Fast - Footed New Hollander”. These are the only birds with gastrocnemius muscle in the back of the lower leg, which has got four bellies (Patak and Baldwin, 1998). Due to the heavyweight, height, running and kicking habits, fractures are very common in bones of pelvic limb of Emu (Shanthilakshmi *et al.*, 2007). Since sparse information was available on the anatomy of Emu, an attempt has been made to study the gross anatomy and biometry of its os-coxae.

MATERIALS AND METHODS

The carcasses of six Emu birds were collected, macerated, cleaned and sun-dried to get the complete skeleton. The os-coxae bones (six) were studied for their gross structure and morphology. Various measurements for different parts of os coxae were made with the help of digital Vernier caliper, inelastic thread, and scale. The data were collected and mean \pm SEs were calculated.

RESULTS AND DISCUSSION

Gross Anatomy of Os-Coxae (Pelvic Girdle)

The os coxae of Emu were a fused pelvic bone comprised of ilium, ischium, and pubis (Figs 1 and 2). However, the two os coxae were less widely separated and arch-shaped.

^{1,2}Department of Anatomy, College of Veterinary Science and Animal Husbandry, Anand Agricultural University, Anand, India

Corresponding Author: KM Panchal, Department of Anatomy, College of Veterinary Science and Animal Husbandry, Anand Agricultural University, Anand, India, e-mail: kmpanchal@aau.in

How to cite this article: Barvalia, I., Panchal, K.M. (2019). Gross and Biometric Studies on Pelvic Bone of the Emu (*Dromaius novaehollandiae*). *Ind J of Vet Sci and Biotech.*, 14(4):21-24

Source of support: Nil

Conflict of interest: None

Submitted: 09/03/2019 **Accepted:** 19/03/2019 **Published:** 20/4/2019

All the three bones were completely ossified in adult birds which remained very difficult to describe separately for the articulation amongst them as well as with the synsacrum. In addition, the pelvic girdle formed the immovable articulation

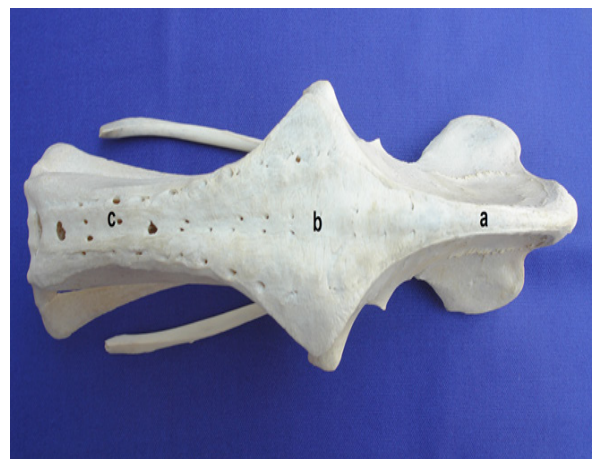


Fig. 1: Pelvic girdle of Emu (Dorsal View) (a) Dorsal fused thick border of the pre-acetabular region, (b) Dorsal fused thickest border of the acetabular region, (c) Dorsal fused thicker border of the post-acetabular region

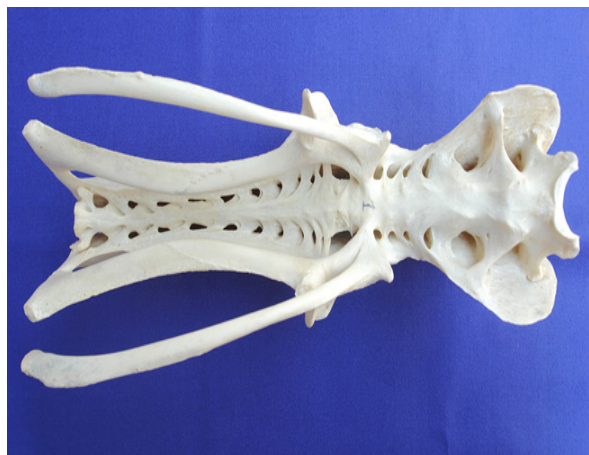

Fig. 2: Pelvic girdle of Emu (Ventral View) (The line indicates Synsacrum

between the bony pelvis and synsacrum. It provided maximum area for the attachments of the massive hind limb muscles. The symphysis pelvis was found open.

In the present study, the ilium was found to be lying nearly vertical to the long axis of the body as reported by Shanthilakshmi *et al.*, (2007). However, the two large os coxae were less widely separated. The pelvic girdle was found to be larger than other domestic birds, which might be related to their bipedal standing posture. The arch shape of the bones of os coxae carrying the weight of the body was in confirmation with the findings of King and McLelland (1984) and Purushotam *et al.*, (2006).

In Emu, there was an absence of pubic and ischial symphysis which was reported in Ostrich and Rhea. This symphysis was thought to prevent compression of the viscera when the birds sit on the ground in case of Ostrich and Rhea (King and McLelland, 1984). As per the reports of Nickel *et al.*, (1977) and Venkatesan *et al.*, (2008), the pelvic girdle formed the immovable articulation between the pelvic bone and vertebral column that provided maximum area for the insertion of the massive hind limb muscles that bears the bulk of the body weight and facilitate fast running. Such articulation provided direct transmission of weight on the ground. The anti-concussion force generated from the ground gets directly transmitted effectively to the vertebral column, which helps in optimum propulsion of the body in the forward direction.

Ilium

Ilium was the largest flat bone of the body. It was compressed laterally, wide towards the cranial end, and comprised of pre-acetabular (A1), acetabular (A2) and post-acetabular (A3) regions (Fig. 3). However, there was no line of demarcation between them. All the three regions were involved in the formation of acetabulum ventrally and had a thick and curved dorsal border. This border was convex and very thick. The thickness was less in the pre-acetabular region which became thickest on the acetabular region. However, in the post-acetabular region, it was thicker than

pre-acetabular region. The thickness reduced from here to the post-acetabular region and was uniform throughout. Medial surface of ilium along its length was completely fused with synsacrum.

Transverse process of lumbo-sacral mass was medially fused with ilia on either side, as described by Purushotam *et al.*, (2006). The dorsal curvature of the ilium was more convex than the Ostrich and Rhea (Hopkins, 1996). It was found that the ilium was divided into two parts, viz., pre- and post-acetabular parts, by a lateral ridge in Emu, Ostrich, and Rhea. These findings were in accordance with Brett and Hopkins (1991) and Shanthilakshmi *et al.*, (2007). The post-acetabular part was larger than the pre-acetabular like those of Goose and Duck, while in case of Fowl it was reverse (Nickel *et al.*, 1977).

Pre-acetabular Region (Fig. 3: A1)

The pre-acetabular region was the cranial part in the form of a rough quadrilateral plate having two surfaces and two borders above acetabulum. The surfaces were lateral and medial. The borders were dorsal, ventral, cranial and caudal. The lateral surface was wide, concave and presented several muscular ridges on it. Dorsal border of the pre-acetabular part was a thin and curved plate that enclosed medially the spinous process of the last two thoracic and lumbar vertebrae along with its fellow. The ventral border was projected forward and outward to enclose more space for the synsacrum. The cranial border was notched at the middle and projected laterally. The caudal border joined with the acetabular part. In Ostrich, the ventral border of pre-acetabular part of ilium was projected forward and outward to enclose more space for the body of the vertebrae. The anterior border at the middle was projected laterally forming a notch (Ushakumary and Geetha Ramesh, 2002).

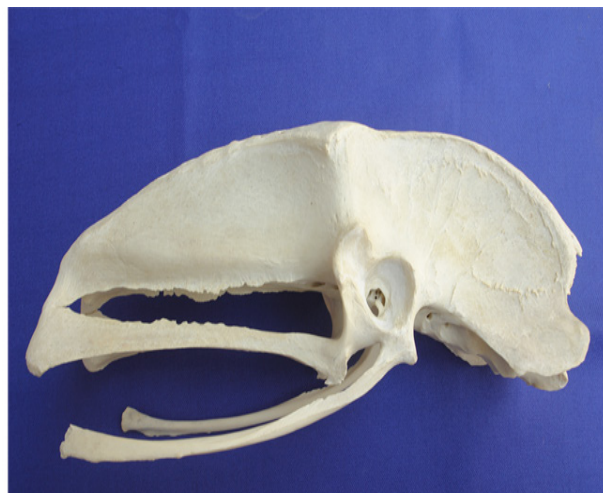

Fig. 3: Pelvic girdle of Emu (Lateral View) showing ilium, ischium and pubis: (A1) Pre-acetabular region of ilium, (A2) Acetabular region of ilium, (A3) Post-acetabular region of ilium, (B1) Anterior vertical part of ischium, (B2) Anterior horizontal part of ischium, (B3) Posterior elongated part of ischium, (C1) Cranial part of pubis, (C2) Caudal part of pubis. Arrows indicate muscular ridges on the pre-acetabular part

Acetabular Region (Fig. 3: A2)

Acetabular region was the central and major part of acetabulum having two surfaces and four borders. The lateral surface was smooth and having only a few muscular ridges. The dorsal border was thickest at the junction between acetabular and post-acetabular regions, which was a wide bony plate. Ventral border continued with the ante-trochanter in front and formed the upper margin of the acetabular cavity. The cranial border joined with the pre-acetabular region and caudal border projected laterally to create wider area for the muscular attachment. Junction of the acetabular and post-acetabular regions was demarcated by a bony prominence (Fig. 1). It was noted that the acetabular region that formed a major part of the acetabulum was the central part of the ilium and comprised of two surfaces and four borders. The wide area for the attachment of the muscles was formed by a cranial border that joined with the pre-acetabular region and the caudal border (Purushoththam *et al.*, 2006).

Post-acetabular region (Fig. 3: A3)

The post-acetabular region was prismatic in appearance and its apex directed caudally having two surfaces and three borders. The lateral surface was concave and presented a bony ridge arising from the acetabulum and obliquely extended caudally (Fig. 1A). The medial surface was closely attached with the vertebrae and did not enclose the iliac fossa. The fossa renalis was absent. The dorsal border was thicker, the ventral border was irregular and formed the roof of ilio-ischiatic foramina. The cranial border was fused with the acetabular region (A2) and also in the formation of the acetabulum. The acetabulum was formed by all the three bones. The acetabulum was in the form of a bony ring and was perforated in the center. Caudodorsal to it was a large bony prominence called "ante-trochanter" that presented an articular surface for trochanter major of the femur (Fig. 3).

The prismatic outline of a post-acetabular part in Emu was contrary to the findings of Nickel *et al.*, (1977) in duck, fowl, and turkey, where it was quadrilateral in shape. In the present study, the lateral surface was concave and presented a bony ridge arising from the acetabulum and extended caudally. Due to the absence of iliac fossa, the kidneys were located just below the lumbo-sacral mass, which makes them more vulnerable to accidental injury during fighting (Venkatesan *et al.*, 2008). In other domestic birds, the acetabulum was like a bony ring and was perforated (King and McLelland, 1984; Shanthilakshmi *et al.*, 2007). In Emu, acetabulum was formed by all the pelvic bones, while in case of fowl and duck pubis was not involved in the acetabulum (Nickel *et al.*, 1977). There was a large ante-trochanter found caudodorsal to the acetabulum similar to the report of Shanthilakshmi *et al.*, (2007).

Ischium

The ischium formed the middle portion of the pelvic girdle and was curved lengthwise towards the midline of the body and joined through acetabulum cranially with ilium and pubis. It was flat laterally and rounded above downward. The ischium was having cranial triangular vertical (B1), cranial horizontal (B2) and caudal elongated (B3) parts (Fig. 3). There was no symphysis ischi. The foramen ischiadicum was in the form of a long ilio-ischiatic incisure. Dorsal margin of this foramen was formed by the ventral border of the post-acetabular region of the ischium. The ventral border was formed by the dorsal border of the ischium. Broad and the caudal end of the ischium was articulated with caudo-ventral end of the ilium and remained separate at the caudodorsal region of the pubis. The ischium was placed ventro-parallel to the post-acetabular part of the ilium that was not in accordance with the findings of Nickel *et al.*, (1977) in domestic fowl. Unlike Ostrich, in Emu, the caudal extremity of the bone was slightly broadened and fused with caudo-ventral end of the ilium by cartilage, but it did not contact with the pubic bone (Venkatesan *et al.*, 2008), which was contrary to the report of Bezuidenhout (1999). The present findings of ischium resembled the report of Venkatesan *et al.*, (2008).

Pubis

Pubis was a thin rod-like bone directed caudally parallel with the ischium and did not project beyond the ilium and ischium. Its cranial part (C1) was involved in the formation of the acetabulum. A large ischio-pubic incisure was observed between pubis and ischium which was divided incompletely by a blunt projection of ischium into oval obturator foramen cranially and elongated caudal slit (caudal part C2) (Fig. 3). The process pectinealis arising from the pubis cranially below the acetabulum was blunt. The cranial most part of ischium and pubis were fused medially with the transverse processes of the lumbosacral mass. Shanthilakshmi *et al.*, (2007) reported widely separated pubis, slightly curved and broaden at the caudal end.

The right and left ischial and pubic bones in Emu did not fuse together to form a pelvic floor as described in Ostrich (Brett and Hopkins, 1991). Pubic bone formed an obturator foramen with ischium, but another foramen was absent in Emu that was described in Ostrich between obturator foramen and ante-trochanter (Ushakumary and Geetha Ramesh, 2002). Nickel *et al.*, (1977) observed that the muscular process on pubis was very well developed in case of domestic fowl and pigeon that gave the attachment to the pectineus muscle, which was rudimentary in Emu.

Biometry of Os Coxae

The mean weight of the os coxae was 261.33±16.52 g. The pre-acetabular part of ilium was quadrilateral and measured 11.87±0.44 cm in length and 9.97±0.42 cm in width. The acetabular and post-acetabular parts measured 8.62±0.36 and 21.59±0.26 cm; and 9.79±0.13 and 6.32±0.22 cm in

width, respectively. Caudo-dorsally there was a strong bony prominence, the ante-trochanter. The ischium was an elongated aborted bone and its anterior horizontal part measured 3.58 ± 0.06 cm in length and 1.45 ± 0.11 cm in width. The posterior elongated part was placed ventro-parallel to the ilium and measured 19.92 ± 0.19 cm in length and 1.57 ± 0.05 cm in width. The pubis was an elongated bone and its cranial part measured 2.25 ± 0.09 cm in length and 2.08 ± 0.11 cm in width. The caudal part measured 22.08 ± 0.33 cm in length and 0.90 ± 0.04 cm in width.

ACKNOWLEDGMENTS

Authors thank the Dean of the Veterinary Faculty Dr A.M. Thaker, and University authorities for the facilities provided for this work.

REFERENCES

- Beizwidenhout, A.J. (1999). Anatomy. In: Ostrich Biology, Production and Health. D.C. Deeming (ed), CAB International, New York.
- Brett, A. and Hopkins, M.S. (1991). Anatomy of Ostriches, Emus and Rheas. In: The Ratite Encyclopedia. 1st edn. Columbia, USA.
- Eastman, M. (2003). The Life of the Emu. London, Sydney: Angus and Robertson.
- Hopkins, B.A. (1996). Anatomy of Ostriches, Emus and Rheas. In: Ratite Encyclopedia.) C. Denowatz and E. Elrod (eds, Ratite Records, Inc., Texas.
- King, A.S. and McLelland, J. (1984). Birds: Their Structure and Function. 2nd edn. Bailliere Tindal, London.
- McLelland, J. (1990). Skeleton. In: A colour Atlas of Avian Anatomy. Wolfe Publishing Ltd. Aylesbury, England.
- Nickel, R., Schummer, A. and Seiferlie, E. (1977). The Skeletal System, Bones of the Pelvic Limb. In: Anatomy of the Domestic Birds. Verlag Paul Parey, Berlin.
- Patak, A.E. and Baldwin, J. (1998). Pelvic limb musculature in the Emu (*Dromaius novaehollandiae*) (Aves: Struthioniformes: Dromaiidae): Adaptation to high speed running. *J. Morphology*, 238(1): 23-37.
- Purushoththam, G., Rajendranath, N. and Promod Kumar, D. (2006). Morphometry of pelvic girdle of Emu (*Dromaius novaehollandiae*). *Indian J. Vet. Anat.*, 18(1): 84-86.
- Shanthilakshmi, M., Chandra Sekhara Rao, T., Jagapathi Ramayya, P.S. and Ravindra Reddy (2007). Gross anatomical studies on the os-coxae and femur of Emu (*Dromaius novaehollandiae*). *Indian J. Poult. Sci.*, 42(1): 61-63.
- Ushakumari, S. and Geetha Ramesh (2002). Gross anatomical studies on the bones of leg, shank and digits of Emu (*Dromaius novaehollandiae*). *Cheiron*, 31: 85.
- Venkatesan, S., Muthukrishnan, S., Sabiha Hayath Basha, Kannan, T.A. and Geetha Ramesh (2008). Gross anatomy of the pelvic girdle of Emu. *Indian Vet. J.*, 85: 1094-1096.

