

Ultrasonographic Fetometry and Fetal Structures during Early Pregnancy in Surti Buffaloes

Mitesh Gaur¹ and G.N. Purohit^{2*}

¹Department of Gynecology and Obstetrics, College of Veterinary and Animal Sciences, Navania, Vallabhnagar, RAJUVAS, Udaipur, ²Department of Gynecology and Obstetrics, RAJUVAS, Bikaner, Rajasthan

Publication Info

Article history:

Received : 05-09-2018

Accepted : 09-09-2018

Published : 17-10-2018

Key Words:

Amniotic vesicle, crown-rump length, fetal heart beat, ultrasonography.

*Corresponding author:

gnpobs@gmail.com

This work is licensed under the Creative Commons Attribution International License (<http://creativecommons.org/licenses/by/4.0/P>), which permits unrestricted use, distribution and reproduction in any medium, provided the original work is properly cited.

Copyright ©: 2018 by authors and SVSBT.

Abstract

Ultrasonographic evaluations of early pregnant Surti buffaloes revealed that the uterine fluid was visible on Day 18 of pregnancy, yet this was not a sure sign of pregnancy. The amniotic vesicle could be detected by Day 26 and was a sure sign of pregnancy. The embryo appeared on Day 26 but with clarity on Day 30. Fetal heart beats were visible from Day 26 and increased significantly ($p < 0.05$) from Day 42 compared to Day 30, 34 and 38 of gestation and remained elevated till Day 62 of gestation. The crown rump length (CRL) of the embryo / fetus could be measured using inbuilt callipers starting from Day 30 till Day 58.

Introduction

Transrectal ultrasonography has gained popularity for evaluation of follicular dynamics (Baruselli *et al.*, 1997; Awasthi *et al.*, 2006), early pregnancy, fetal deaths and fetal growth (Karen *et al.*, 2007; Ali and Fahmy, 2008; Russo *et al.*, 2009). Real time B-mode ultrasound was used to detect and monitor the early conceptus, its growth and its anatomical features in Murrah (Pawshe *et al.*, 1994), Egyptian (Karen *et al.*, 2007), Nili Ravi (Naseer *et al.*, 2012), Bangladeshi (Rabidas and Gofur, 2017) and Mediterranean

(Russo *et al.*, 2010) buffaloes. Sonographic fetometry was performed in a few studies (Pawshe *et al.*, 1994; Ali and Fahmy, 2008). Similar evaluations in Surti breed of buffaloes are unavailable. The present study evaluated the early appearance of embryo/fetus and its annexes during pregnancy.

Materials and Methods

Surti buffaloes belonging to the elite herd of Network Project on Buffalo Improvement at Livestock Research Station, Vallabhnagar, district Udaipur (RAHUVAS) were included in this study.

Buffaloes inseminated during a spontaneous estrus (n=9) detected using a teaser (Purohit and Rao, 2018) and early pregnant buffaloes of the herd (n=19) were examined every 3-4 days by transrectal ultrasonography (Exago, ECM-Noveko International Inc., Angoulême, France) equipped with a 5.0-7.5 MHz linear-array transducer for early appearance of fetus and its annexes starting from Day 18 of insemination till Day 90. Only 5 of the inseminated buffaloes were found pregnant thus total 24 buffaloes were examined in the present study. The first appearance of uterine fluid, amniotic vesicle, embryo and its heart beat and crown rump lengths were measured/recorded and the images were saved. The data obtained were analyzed as per statistical procedures described previously (Snedecor and Cochran, 1994).

Results and Discussion

Uterine fluids

On Day 18 post-AI, a very little amount of anechoic fluid was seen in the lumen of uterine horn ipsi-lateral to CL (Fig.1) indicating sign of probable pregnancy. At this stage the echoic uterine wall along with anechoic fluid could be easily identified. In none of the animals examined at this stage the embryo proper could be visualized. The appearance of fluid in the uterine lumen was not a sure sign of pregnancy as 4 animals that evidenced fluid on Day 18 were found to be non-pregnant at later days of evaluation. Similar findings were previously reported by Pawshe *et al.*, (1994).

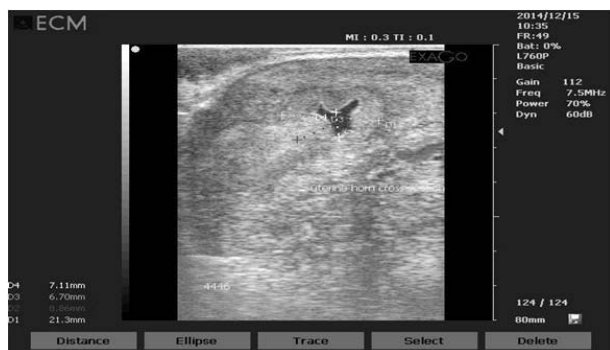

Fig. 1 : Sonograph showing the presence of little amount of anechoic fluid in the lumen of uterine horn on Day 18 post AI in a Surti buffalo.

Amniotic vesicle

On day 26, the amount of anechoic fluid in the uterine lumen increased and compartment

formation was recorded. Anechoic amniotic vesicle formation was observed in fluid filled uterine chamber and could be easily identified (Fig. 2).

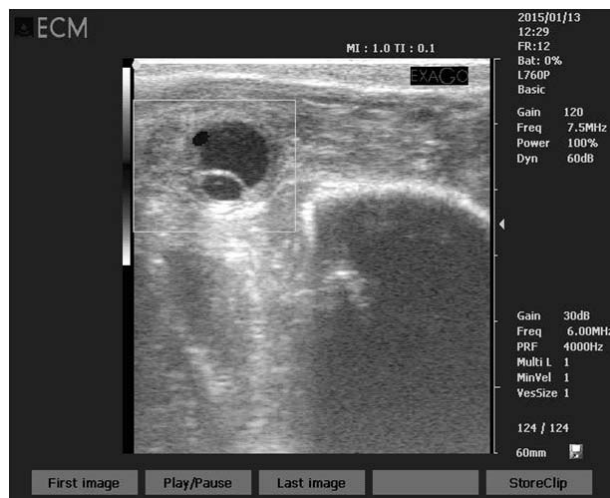

Fig. 2 : Sonograph depicting the presence of amniotic vesicle on Day 26 as confirmatory diagnosis of early pregnancy in a Surti buffalo.

The amount and size of anechoic fluid increased with advancement of gestation. The confirmatory diagnosis of early pregnancy was established with the finding of the amniotic vesicle as all buffaloes with evidence of amniotic vesicle were found confirmed pregnant. There is variation in reports on first appearance of uterine fluid from Day 19 (Pawhse *et al.*, 1994) to Day 21-22 (Herera *et al.*, 2007; Ferreira *et al.*, 2012; Sharma *et al.*, 2012), however, these workers also mentioned that the appearance of uterine fluid was not a definitive sign of pregnancy in buffaloes at this time and for definitive diagnosis of pregnancy examination at later stage seem mandatory. Similar to the present findings, embryo and embryonic membranes were observed on Day 26 or 27 in previous studies on buffaloes (Groza *et al.*, 2012; Sharma *et al.*, 2012). In a few recordings during the present study the embryo was not visible, although the amniotic vesicle was clearly visible. This could be due to the different angle of placement of the probe during examination.

Embryo

The embryo proper could although be visualized on Day 26 of gestation as a small echogenic spot within the amniotic vesicle (Fig. 2) however, it was clearly visible as an echoic structure on Day 30 of pregnancy surrounded by

anechoic amniotic fluid (Fig. 3). Starting the same day the crown rump length of a crescent shaped embryo could also be measured. The amniotic membrane surrounding the embryo could clearly be differentiated on Day 38 of gestation and on later days of scanning. Ferreira *et al.* (2011) assessed buffalo embryo on day 25.18 ± 1.91 post-breeding whereas Pawshe *et al.* (1994, 2011) observed embryo on day 19.0 ± 1.69 of gestation in buffaloes and in cattle on day 22.5 ± 0.7 of gestation which is earlier than present study. This difference observed may either be due to species variation, expertise of operator.

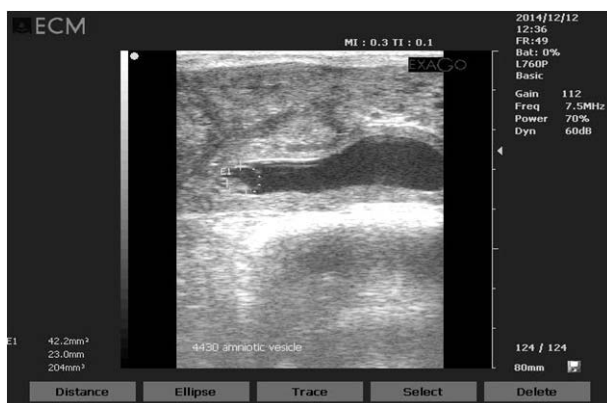


Fig. 3 : Sonograph showing the presence of embryo as an echoic structure on Day 30 of pregnancy surrounded by anechoic amniotic fluid in a Surti buffalo.

Fetal heart beat

The fetal heart could be visualized by Day 26 of gestation. It appeared as a flickering structure on the screen and the beats could be measured from Day 34 (Fig. 4) onwards. Fetal heart beats could be visualized and recorded till Day 90 of gestation. Fetal heart beats increased significantly ($P < 0.05$) from Day 42 compared to Day 34 and 38 of gestation and remained elevated till Day 62 of gestation. Thereafter, from Day 66 the fetal heart beats returned to values that were non-significantly higher compared to heart beats on Day 34. The fetal heart beats could not be visualized beyond Day 90 of gestation as the fetus was located more cranially in abdominal cavity beyond the reach of transducer. Pawshe *et al.* (1994) observed fetal heart beats of 203.8 ± 9.0 on day 29.6 ± 1.57 and the heart beats decreased to 150 beats per minute on day 62. The variations in fetal heart beat may be due to breed or individual difference. Pawshe and Purohit

(2013) reported that embryo and fetal heart beats are first visible from Days 25 to 29 based on findings of different studies.

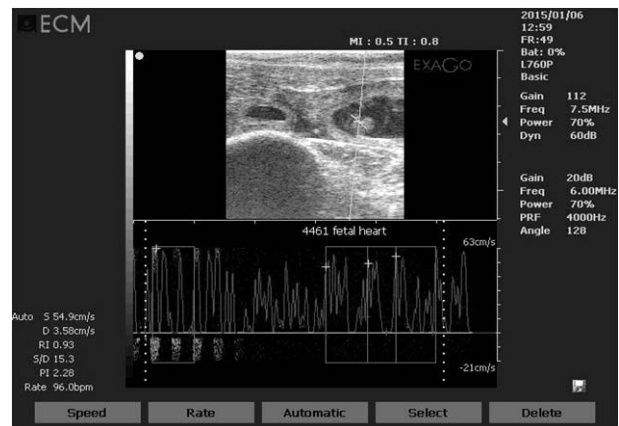


Fig. 4 : Sonograph showing the embryonic heart beats as a flickering on the screen by day 26 of pregnancy in a Surti buffalo.

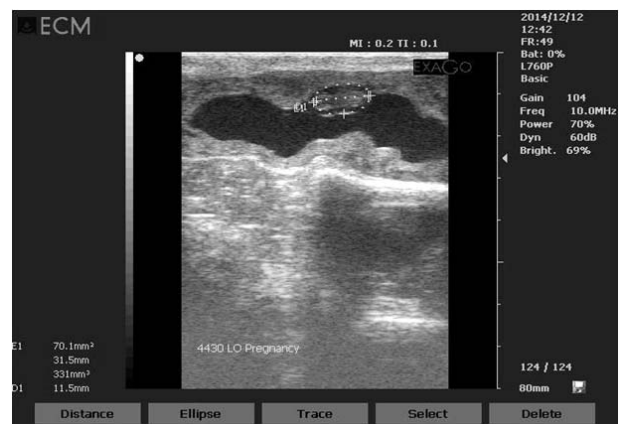

Fig. 5 : Sonograph demonstrating the first measurement of CRL on Day 30 of pregnancy in a Surti buffalo.

Crown rump length (CRL) of the fetus

The fetus was seen as elongated hyper-echoic structure surrounded by hypo-echoic fluid in the lumen of uterus. The crown rump length (CRL) of the embryo and/or fetus could be measured using inbuilt callipers starting from Day 30 till Day 58 of gestation. The CRL was 11.41 ± 1.56 mm on Day 30 (Fig. 5) and this increased sequentially for the days of gestation evaluated. Compared to CRL length on Days 30 and Day 34 the increase in CRL was significant ($p < 0.05$) on Days 38 and Day 42. There was further gradual and significant ($P < 0.01$) increase in the CRL on Days 46 and 50, and again on Day 54 and Day 58 compared to previous days records to attain a CRL of 46.34 ± 2.73 mm on

Table 1: Crown rump length (Mean \pm SE) of embryo/fetus during different days of gestation in Surti buffaloes

Days of Gestation (days)	CRL (mm)
26	11.41 \pm 1.56 ^a
30	11.5 \pm 0.84 ^a
34	13.57 \pm 1.10 ^a
38	17.2 \pm 0.73 ^b
42	18.01 \pm 0.86 ^b
46	28.30 \pm 0.96 ^c
50	29.15 \pm 1.72 ^c
54	41.27 \pm 2.16 ^d
58	46.34 \pm 2.73 ^d

Mean values with different superscripts (a, b, c, d, e) differ significantly (P<0.05)

Day 58 (Table 1). After day 60, image of complete fetus could not be scanned due to large size of fetus that exceeded the scanning range of transducer used. Pawshe *et al.* (1994) recorded increase in CRL of the embryo from 4.2 \pm 0.89 to 53.6 \pm 2.11 mm from Day 19 to Day 62 in buffaloes. Groza *et al.* (2012) recorded CRL on Day 40 as 50 mm which increased to 120 and 150 mm on Days 60 and 80, respectively, in buffaloes. They recorded much greater CRL on Day 60 than that of present finding on Day 58 (120 vs. 46.34 mm), which may be due to position of the fetus, expertise of operator, ultrasound instrument and breed.

Acknowledgement

The help extended by the Dr. Dinesh Jhamb, Assistant Professor, CVAS, Navania is thankfully acknowledged.

Conflict of Interest

The authors have no conflicts of interest.

References:

Ali, A. and Fahmy, S. (2008). Ultrasonographic fetometry and determination of fetal sex in buffaloes (*Bubalus bubalis*). *Anim. Reprod. Sci.*, **106**: 90-99.

Awasthi, M.K., Khare, A., Kavani, F.S., Siddiquee, G.M., Panchal, M.T. and Shah, R.R. (2006). Is one-wave follicular growth during the estrous cycle a usual phenomenon in water buffaloes

(*Bubalus bubalis*)? *Anim. Reprod. Sci.*, **92**: 241-253.

Baruselli, P.S., Mucciolo, R.G., Visintin, J.A., Viana, W.G., Arruda, R.P., Madureira, E.H., Oliveira, C.A. and Molero-Filho, J.R. (1997). Ovarian follicular dynamics during the estrous cycle in buffalo (*Bubalus bubalis*). *Theriogenology*, **47**: 1531-1547.

Ferreira, J.C.P., Martin, I. and Irikura, C.R. (2011). Ultrasonographic monitoring of early pregnancy development in Murrah buffalo heifers (*Bubalus bubalis*). *Livestock Sci.*, **138**: 174-179.

Groza, I., Tomai, G. and Cenariu, M. (2012). Ultrasonography, a modern tool for pregnancy diagnosis and identification of fetal structures in domestic buffaloes. *Bull UASVM Vet. Med.*, **69**: 1-9.

Herrera, P., Campo, E. and Denis, R. (2007). Relationship between the size of fetal structures and time of pregnancy in river buffaloes. *Rev. Salud. Anim.*, **29**: 28-31.

Karen, A., Darwish, B. and Raman, A.D. (2007). Accuracy of ultrasonography and pregnancy associated glycoprotein test for pregnancy diagnosis in buffaloes. *Theriogenology*, **68**: 1150-1155.

Naseer, Z., Ahmed, M., Khan, M.I.R., Ahmed, E., Tahir, M.Z. and Singh, J. (2012). Effect of GnRH and estradiol benzoate on follicular wave emergence, estrus, ovulation and pregnancy rate in CIDR treated Nili Ravi buffaloes. *J. Anim. Plant Sci.*, **22**: 142-146.

Pawshe, C.H., Patil, S.R., and Ingawale, M.V. (2011). Ultrasonography a diagnostic tool for detection of early pregnancy and study of embryonic development in buffalo and cattle. *Intas Polivet*, **12**: 1-4.

Pawshe, C.H. and Purohit, G.N. (2013). Approaches for diagnosis of pregnancy in female buffaloes. In: *Bubaline Theriogenology*, Purohit GN (Ed) www.ivis.org A5708.0613.

Pawshe, C.H., Apparao, K.B.C. and Totey, S.M. (1994). Ultrasonographic imaging to monitor early pregnancy and embryonic development in buffalo (*Bubalus bubalis*). *Theriogenology*, **41**: 697-709.

Purohit, G.N. and Rao, T.K.S. (2018). Estrus detection in buffaloes. In: *Bubaline Theriogenology*, Purohit G.N. (Ed.). International Veterinary Information Service, Ithaca NY (www.ivis.org), Last updated: 12-Mar-2018; A5704.0318

- Rabidas, S.K. and Gofur, R.M. (2017). Synchronization of estrus using Ovsynch protocol and fixed timed artificial insemination in indigenous dairy buffaloes: An effective buffalo breeding program in Bangladesh. *Asian J .Biol.*, **2**: 1-8.
- Russo, M., Luise, L., Rossi, P., Grasso, F.L., Cocchia, N. and Catone, G. (2009). Ultrasonographic appearance of early embryonic mortality in buffalo (*Bubalus bubalis*). *Italian J. Anim. Sci.*, **8**(sup 2): 138-140.
- Russo, M., Vecchio, D., Neglia, G., Pacelli, C., Prandi, A., Gasparini, G., Zicarelli, L., D-Occhio, M.J.C. and Campanile, G. (2010). Corpus luteum function and pregnancy outcome in buffaloes during the transition period from breeding to non-breeding season. *Reprod. Domest. Anim.*, **45**: 988-991.
- Sharma, R.K., Singh, J.K. and Khanna, S. (2012). Fetal age determination in Murrah buffaloes from day 22 through 60 with ultrasonography. *Indian J. Anim. Sci.*, **82**: 374-376.
- Snedecor, G.W. and Cochran, W.G. (1994). *Statistical methods. 8th edn.* Oxford & IBH Publishing Co., Calcutta, India.

□