
Submitted : 15-02-2018

Accepted : 14-03-2018

Published : 08-04-2018

Clinical Evaluation of Surgical Procedures for Corneal Ulcer in Dogs

Priyanka Pandey, A. Shahi, D. Kumar and M.K. Shukla

Department of Veterinary Surgery and Radiology,

College of Veterinary Science and AH,

Nanaji Deshmukh Veterinary Science University, Jabalpur- 482001, Madhya Pradesh

Corresponding Author: itsmepriyankapandey@gmail.com

This work is licensed under the Creative Commons Attribution International License (<http://creativecommons.org/licenses/by/4.0/P>), which permits unrestricted use, distribution and reproduction in any medium, provided the original work is properly cited.

Copyright @: 2018 by authors and SVSBT.

Abstract

The present study was conducted on 12 dogs, irrespective of age sex and breed, having corneal ulcer to evaluate the response of surgical procedures. The animals were randomly divided into two groups, in group I temporary tarsorrhaphy and in group II third eyelid flap surgery was performed along with pre and post-operative systemic and local medication. Preoperative ophthalmoscopic examination was performed before starting the treatment, i.e. day 0, to check the general health status of the animals, followed by day 15, 30, 45 and 60 post-operative examination to record the healing of corneal ulcer. In group I lesser complications were observed as compared to group II and 66.66% and 50.00% dogs recovered without scar formation on 60th post-operative day in group I and II, respectively. Thus temporary tarsorrhaphy was observed superior then the third eyelid flap surgery as well as combination of moxifloxacin and flurbiprofen was found satisfactory for the healing of corneal ulcer.

Key words: Dogs, Corneal ulcer, Temporary tarsorrhaphy, Third eyelid flap surgery, Moxifloxacin.

Introduction

Dogs are affected by various ocular disorders, such as cataracts, glaucoma, corneal ulcer, corneal opacity, lens luxation, cherry eye, uveitis, corneal dystrophy and dry eye. Corneal ulceration or ulcerative keratitis is one of the most common extra-ocular diseases identified in dogs (Gelatt, 2000). The principles in treatment of corneal ulcer include removal of the primary cause, reduction of inflammation, control of infection, enhancement of corneal healing and minimization of corneal scar. Surgery still remains the effective treatment of corneal ulcer (Wilkie and Whittaker, 1997). Temporary tarsorrhaphy and third eyelid flap surgery are used to protect the cornea during a short period exposure and both are performed to treat the infected corneal ulcer. Looking to the high detrimental effect of corneal ulceration in dog, the present study was designed to evaluate two surgical procedure i.e. Temporary tarsorrhaphy and third eyelid flap surgery along with newer antibiotic and anti inflammatory drugs to promote corneal ulcer healing.

Materials and Methods

The study was conducted on twelve clinical cases of corneal ulcer in dogs, presented at Teaching

Veterinary Clinical Complex (TVCC), irrespective of age, sex and breed. All the 12 dogs were randomly divided into two equal groups, six dogs in each, corneal ulcer were treated with temporary tarsorrhaphy technique in Group I (Lewin, 2000) and third eye lid flap technique in group II (Morgan, 2004) along with medicinal treatment.

Clinical examinations included rectal temperature (°F), respiration rate (per minute), pulse rate (per minute) and palpebral mucous membrane prior to treatment to judge the health status of the animal. Eye was palpated by index finger to check the intra-ocular pressure, vision was judged by palpebral reflex and menace (Blink) reflex in addition, epiphora, conjunctivitis, hyphema, foreign body and location of ulcer (axial, paraxial, inferior nasal, inferior temporal, perilimbal) were also recorded. Pre-operative ophthalmic examination was performed just before starting the treatment. i.e. on 0 day, which included schirmer tear test, fluorescein dye test, direct ophthalmoscopic examination, ultrasonographic. TLC, DLC, Hb and Blood glucose were determined following standard routine methods.

Preoperative Systemic treatment included moxifloxacin hydrochloride @ 5-10 mg/kg b.wt. orally od, Meloxicam @ 0.2-0.3 mg/kg b.wt. i/m od for 3 days, Multi-vitamins, minerals and ginseng capsules od, orally and instillation of eye drop containing moxifloxacin (0.5%) one to two drops qid, flurbiprofen (0.03%) two drops qid, hydroxypropyl methylcellulose (0.1%) two drops and atropine sulphate eye ointment (1%) topically bid. Both the surgical procedures i.e. Temporary tarsorrhaphy technique (Lewin, 2000) and third eye lid flap technique (Morgan, 2004) were performed under general anaesthesia induced using Inj. atropine sulphate @ 0.04 mg/kg b.wt i/m, after 5 minutes Inj. xylazine hydrochloride @ 1.5 mg/kg b.wt i/m and after 10 minute Inj. ketamine hydrochloride @ 6 mg/kg b.wt i/m and maintained on ketamine hydrochloride intravenously. Post-operative grading of corneal ulcer was done as per score card given by Harrison (1975) depending on the depth of ulcers as mild, moderate and severe. Healing was recorded on day 15, 30, 45 and 60 post-operatively .

Results and Discussion

In all the twelve dogs rectal temperature, respiration rate and pulse rate ranged between 101.6 to 102.6 °F, 20 to 26 per minute and 91 to 96 per minute respectively, which were within in the normal physiological limits. Normal pink colour palpebral mucous membrane was observed in all the dogs.

Total leukocyte count ranged between 7 to 9 thousand/ μ l, haemoglobin between 13 to 16 g/dl and differential leukocyte count was within normal physiological range. In all the dogs blood glucose level ranged between 102 mg/dl to 110 mg/dl which was within the normal reference range.

Pre-operative ophthalmic examination

In gross examination majority of the dogs showed mild to moderate lacrimation, congestion and mild corneal opacity accompanied. Intraocular pressure was normal and none of the dog was diagnosed for glaucoma with corneal ulcer. All the dogs responded to menace reflex, direct pupillary light reflex and dazzle reflex.

In the present study schirmer tear test was found higher (22 to 26 mm/min) in all the dogs indicating higher lacrimation except in one case (4 mm/min). There was continuous itching, pawing, irritation, pain and photophobia in the ulcerative cornea, which resulted into excessive lacrimation ,this may be reason for high range of schirmer test. Our findings are in consonance with the findings of Murphy (2015). The tonometry, direct ophthalmoscopy and ultrasonographic examination was performed in all the dogs but no abnormality and intraocular pathology was seen in any of the dog.

Fluorescein dye test was applied in all the dogs which showed the different location of corneal ulcer along with their size. Majority of the corneal ulcers were located in inferior temporal (33.33%) followed by axial (16.67%), peripheral (16.67%) and inferior nasal (16.67%) positions. Paraxial and perilimbal location was also observed in one dog each. The size of corneal ulcer was measured and it ranged between 2 mm to 5 mm. Majority of the dogs were suffering with moderate corneal

Table 1: Pre-operative ophthalmic evaluation in dogs suffering with corneal ulcer

Group	Case No.	Gross examination	Schirmer tear test (mm/min.)	Location of ulcer	Size of corneal ulcer (mm/min.)	Depth of ulcer	Grading of corneal ulcer
I	1	Mild lacrimation, congestion and corneal opacity	23	Inferior temporal	4	Superficial	Moderate
	2	Mild lacrimation, congestion	25	Inferior temporal	3	Superficial	Moderate
	3	Mild lacrimation, congestion	23	Axial	3	Superficial	Moderate
	4	Mild lacrimation	24	Inferior nasal	2	Superficial	Moderate
	5	Mild lacrimation,	22	Peripheral	3	Superficial	Moderate
	6	Mild lacrimation, congestion, mild corneal opacity	24	Paraxial	5	Mid-stroma	Severe
II	7	Mild lacrimation, congestion and corneal opacity	26	Peripheral	3	Superficial	Moderate
	8	Mild lacrimation, congestion	24	Axial	2	Superficial	Moderate
	9	Mild lacrimation, congestion	22	Perilimbal	4	Superficial	Moderate
	10	Mild lacrimation, mild corneal opacity	23	Inferior temporal	5	Mid-stroma	Severe
	11	Mild lacrimation, congestion	25	Inferior nasal	3	Superficial	Moderate
	12	Congestion	4	Inferior temporal	2	Superficial	Moderate

ulcer (83.33%) and less cases (16.66%) were reported for severe corneal ulcer (Table 1).

Post operative therapy and evaluation of the corneal ulcer healing

Tab. moxifloxacin hydrochloride, meloxicam and multi vitamins, minerals and ginseng tablets were given as systemic treatment and eye drop moxifloxacin, flurbiprofen and atropine sulphate eye ointment was applied topically. This treatment protocol was found effective to control infection and promote corneal ulcer healing. There are number of studies in human patients and also in dogs which used this protocols for the treatment of corneal ulcer (Raymond, *et al.* 2012 and Sharma *et al.* 2013).

Two out of 12 dogs showed complete healing and only scar was present on 15th post-operative day while in 10 dogs the size of corneal ulcer reduced. On 30th post-operative day corneal ulcers were completely healed with scar except one where scar was not observed. On 45th day, 50% dogs of group I recovered completely and transparency of cornea was maintained, whereas in rest slight abraded area/scar at the point of ulcer was observed. In group II complete healing without scar

formation was observed in 33.33% cases and scar was present in 66.66% cases. On 60th day in most of the dogs scar was not observed (Fig. 1 and 2). Schoster (2012), Ramani *et al.* (2013) and Singh *et al.* (2015) reported that 78.58% cases of superficial corneal ulcer were completely healed after 2 to 3 weeks and 56% cases of deep corneal ulcer healed after 45 days of surgery and only scar was present in deep corneal ulcer.

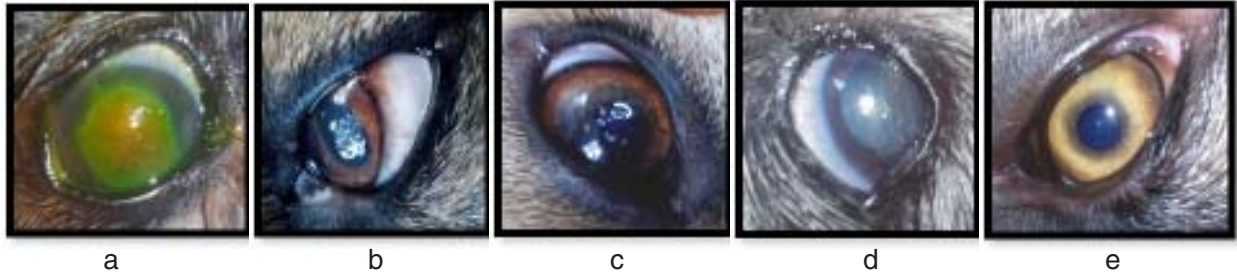


Fig 1: Clinical evaluation of corneal ulcer healing in Group I: (a) ulcer at 0 day (b) scar formation at 15th day, (c) reduced scar at 30th day, (d) no scar at 45th day and (e) transparent cornea at 60th post-treatment.

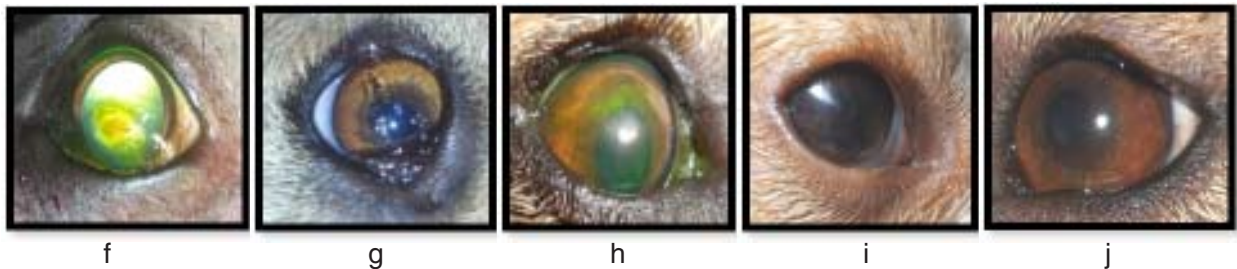


Fig 2: Clinical evaluation of corneal ulcer healing in Group II: (a) ulcer at 0 day, (b) scar formation at 15th day, (c) no scar at 30th day, (d) no scar at 45th day and (e) transparent cornea at 60th post treatment day.

Complications

In the present study various complications were observed like Ocular discharge, swelling of eye lid margin, inflammation of third eye lid, loosening of suture, discomfort and continuous itching by paw, this may be because of fact that dogs feel uneasiness and discomfort due to bandage, Elizabethan collar and irritation due to suture after surgery.

Conclusions

In group I lesser complications were observed as compared to group II and 66.66% and 50% dogs recovered without scar formation on 60th post-operative day in group I and II respectively. Thus temporary tarsorrhaphy was observed superior then the third eyelid flap surgery. Combination of moxifloxacin and flurbiprofen was found satisfactory for the healing of corneal ulcer.

Acknowledgement

The authors express profound sense of gratitude to the Dean, College of Veterinary Science and AH, Jabalpur for the facilities provided. Senior author is thankful to major advisor and members of advisory committee for their constant guidance and help to carry out this research work smoothly.

Conflict of Interest: All authors declare no conflict of interest.

References:

- Gelatt, K.N. (2000). Disease and surgery of canine cornea and sclera. *J. Vet. Opth.*, **4**: 700-725.
 Harrison, S.M. (1975). Grading corneal ulcers. *Annals Opth.*, **7**(4): 537-539.

- Lewin, G.A. (2000). Temporary lateral tarsorrhaphy for the treatment of lower lateral eyelid entropion in juvenile dogs. *American Journal of Veterinary Surgery*, **146**: 439-440.
- Morgan, R.V. (2004). Common corrective and protective eyelid surgeries. *J. Vet. Med.*, vol: 2 364-368.
- Murphy, C.J. (2015). The Genetics of keratoconjunctivitis sicca in west highland white terriers principal investigator. *Am. J. Vet. Opth.*, **22**: 1098-1106.
- Ramani, C., Rambabu, N., Dsouza, J., Vairamuthu, S. and William B.J. (2013). Surgical bacteriology and grading of corneal ulcers in dogs a retrospective study in dogs. *Tamilnadu J. Vet. & Anim. Sci.*, **4**: 250-252.
- Raymond, L. M., Gangwani, R.A., Lester, W.H. and Jimmy, S. M. (2012). New Treatments for Bacterial Keratitis. *Journal of Ophthalmology*, **14**: 15-21.
- Schoster, J.V. (2012). Complicated Corneal Ulcers: Microbial Keratitis in dogs. *American Journal of Veterinary Ophthalmology*, **16**: 684-691.
- Sharma, N., Goel, M., Bansal, S., Agarwal, P., Titiyal, J.S., Upadhyaya, A.D. and Vaipayee, R.B. (2013). Diseases of cornea in dogs. *Journal of Veterinary Ophthalmology*, **6**: 1173-1176.
- Singh, N.P., Jhirwal, S.K. and Gahlot, T.K. (2015). Management of Corneal Ulcer: Research and reviews. *J. Vet. Sci.*, **2**: 4-5.
- Wilkie, D.A. and Whittaker, C. (1997). Surgery of the cornea. *Vet. Clin. North Am. Small Anim. Pract.*, **27**: 1067-1107.

□