

### SURGICAL MANAGEMENT OF ORAL SQUAMOUS CELL CARCINOMA IN A CAMEL (*Camelus dromidarius*)

Biswadeep Jena, Abrar Ahmed, Nilesh Kumar Pagrut , R.P. Tiwari and G.K. Mishra

Department of Veterinary Surgery & Radiology,

M.J.F. college of Veterinary and Animal Sciences, Rajasthan University of Veterinary and  
Animal Sciences Chomu, Jaipur

Received 17-1-2015 Accepted 14-2-2015

Corresponding Author : biswadeep44@gmail.com

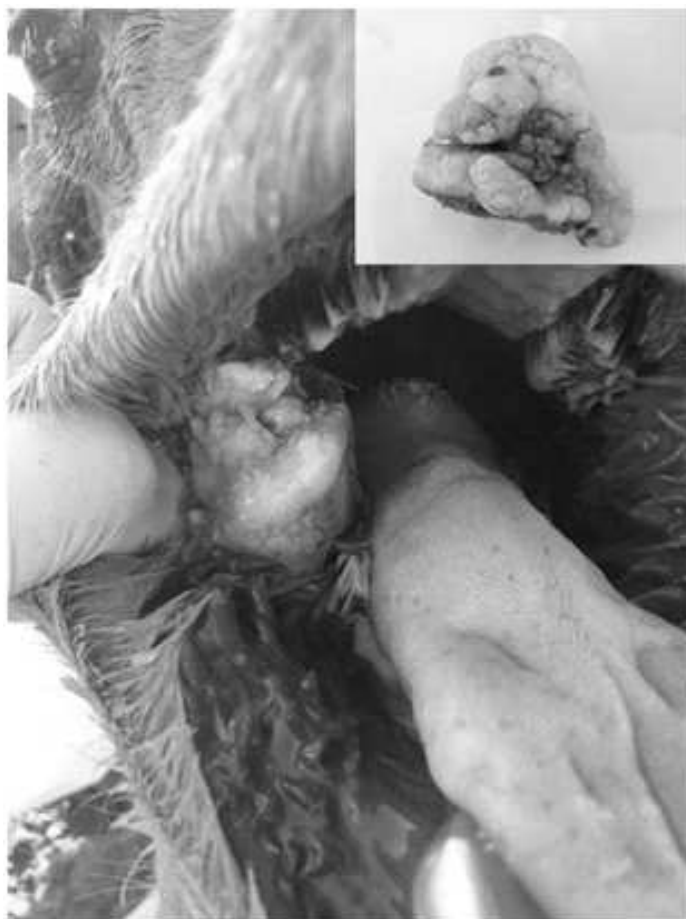Squamous cell carcinoma (SCC) is a malignant tumour of squamous epithelial cells. It is a common neoplasm affecting all domestic animals, but most commonly the dog, horse and cat. When SCC occurs in the mouth and throat, it is called oral squamous cell carcinoma (Moulton, 1978). In camel, SCC has been reported frequently on the flank, caudal to the chest pad, side of the hock, the hard palate, nasal cavity, interdigital space and dorsal part of the nail of the foot (Siddiqui and Telfah, 2010). But SCC on cheek mucosal wall has rarely been reported. The present study describes the oral SCC on cheek mucosal wall in a Bikaneri Camel.

#### CASE HISTORY AND CLINICAL EXAMINATION

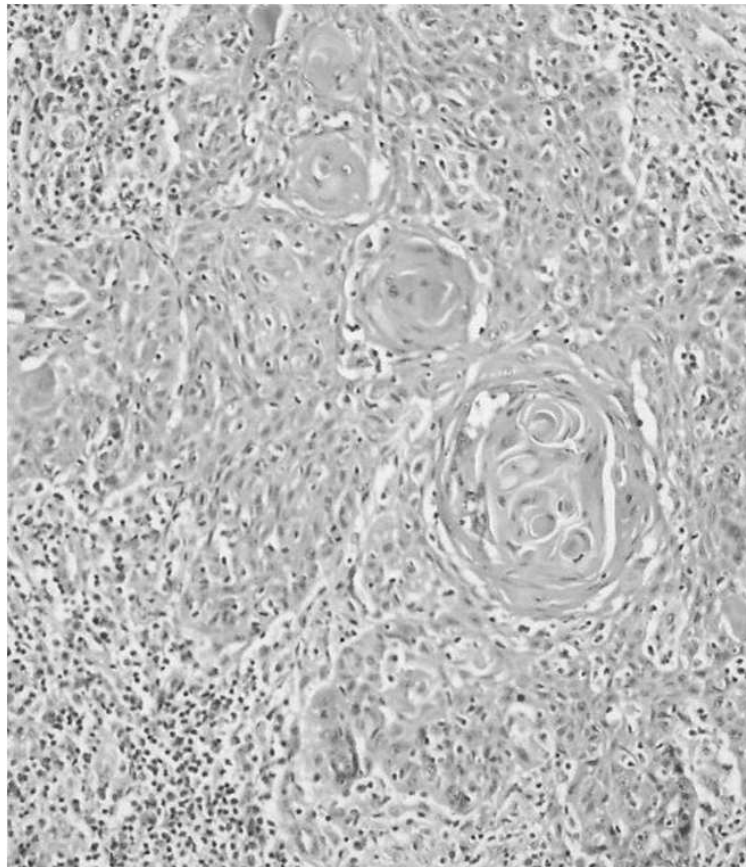
A Bikaneri she camel, aged about 12 years, weighing approximately 650 kg, was present to Department of Veterinary Surgery and Radiology, M.J.F. College of Veterinary and Animal Science Chomu, Jaipur with history of progressive swelling in its right cheek wall from the last 10 months. Direct visualization of the oral cavity revealed a solid, irregularly shaped, greyish-pink mass consisted of multiple ulcerated cauliflower like lobular growth was seen attached among the caudally directed oral papillae of right cheek mucosa (Photo 1). The animal was showing signs of dysmastia and drooling with flakes of blood, dysphagia, inanition, and progressive loss of condition, without any systemic illness. Based on history and clinical examination it was diagnosed to be a case of tumour - Hence a decision was taken to exteriorize the abnormal mass.

#### TREATMENT AND DISCUSSION

The animal was fasted for 24 hours. For exteriorization of the abnormal mass the animal was restrained in sternal recumbency



**Fig. 1:** Camel showing solid, irregularly shaped, greyish-pink cauliflower like abnormal mass attached to right cheek mucosal wall. Inset showing exteriorized abnormal mass.



**Fig 2:** Histopathology showing irregular nests of stratified squamous cells, abundant keratinized cytoplasm, laminated “keratin pearls”, large pleomorphic nuclei, high mitotic figures and variable amount of fibrous tissue (H & E, X100).

and deep sedation was achieved by intravenous administration of 10 ml xylazine (Xylaxin®; Indian Immunologicals Ltd ) After attainment of sedation, the external jugular vein was catheterised and approximately 5 litres of normal saline was administered intra-operatively. Pre-emptive antibiotic (60 ml Oxytetracycline®; Zydus AHL) was administered slowly through intravenous route. Also before surgery, non-steroidal anti-inflammatory drug 20 ml meloxicam (Melonex®; Intas Pharmaceutical Ltd) was administered intramuscularly. The animal's mouth was opened by an assistant after application of a rope each at upper and lower jaw followed by exposure of inner wall of right cheek. The affected area was washed with potassium permanganate solution (0.001%). 10 ml of 2% Lidocaine (Xylocaine®; Astra Zeneca Ltd) local anaesthetic solution was infiltrated at the base of the abnormal mass. After 10 minutes, the tongue was pulled out and the mass was clamped with the help of artery forceps at its base. The neck of the mass held firmly and the complete mass was excised along with the healthy tissue of the cheek wall. The excised tissue was submitted for histopathology. Haemorrhage was controlled by application of cotton swab soaked with adrenaline bitartrate (Vasocon®; Neon Labs, India). The wound was closed with the help of absorbable suture (No. 1 Ethicon® chromic catgut) in simple interrupted pattern with buried knots.

The animal was recovered within 60 minutes after the onset of sedation. Post-operative care consists of irrigation of oral cavity by luke warm potassium permanganate solution (0.001%), antibiotic (60 ml Oxytetracycline®; Zydus AHL) and analgesic (20 ml meloxicam, Melonex®; Intas Pharmaceutical Ltd) cover for 5 days. Owner was advised to offer succulent green feed and

molasses solution for 3 weeks. During re-examination after 3 weeks, there was little evidence of the trauma to the cheek wall. The camel recovered uneventfully and was permitted to return to its normal draught duties.

The selected specimens were fixed in 10% buffered formalin (pH = 7.2), then sectioned in 5  $\mu$ m and stained with hematoxylin and eosin. Histopathological examination revealed irregular nest of stratified squamous cells invading the submucosa with copious keratinized cytoplasm and large pleomorphic nuclei. High mitotic figures, numerous laminated "keratin pearls" and variable amount of fibrous tissue were also evident (Photo 2). Hence above histopathological findings of the excised mass confirmed it to be a squamous cell carcinoma (Vegad and Swamy, 2010).

SCCs are relatively common in the oral mucosa of adult dogs and cats, but occur less frequently in other species (Carton and McGavin, 1995). It is an aggressive cancer and is often not diagnosed until the tumour is advanced. Nontonsillar SCCs are locally invasive with a low rate of metastasis, and the prognosis is good with aggressive and complete surgical resection, radiation therapy, or both. Prognosis for oral SCC entirely depends on the location of the tumour and metastatic rate. Tumour present in the rostral oral cavity has a low metastatic rate as compared to the tumour present in caudal tongue and tonsil (Dixon and Gerard, 2006). Although metastasis of SCC to regional lymph nodes have been observed in the various species (Moulton, 1978) but no clinical evidence of regional lymph node metastasis was observed in the present case.

#### REFERENCES :

- Carton, W.W. and McGavin, M.D. (1995). Thomason's special veterinary pathology, 2nd edn, St. Louis, Missouri, Mosby, p. 10.
- Dixon, P.M. and Gerard, M.P. (2006). Oral cavity and salivary glands. In: Auer, J. A., and Stick, J. A. (Eds) Equine surgery, 3<sup>rd</sup> edn, WB Saunders, St. Louis, Missouri, p. 341-342.
- Moulton, J. E. (1978). Tumours in domestic animals, 2<sup>nd</sup> edn, University of California Press, Berkeley, Los Angeles, London, p. 45, 248.
- Siddiqui, M.I. and Telfah, M.N. (2010). Surgical Oncology. In: A Guide Book of Camel Surgery. 1st edn, Abu Dhabi Food Control Authority, United Arab Emirates, p. 189-200.
- Vegad, J.L. and Swamy, M. (2010). Digestive system. In: A textbook of Veterinary Systemic Pathology, 2<sup>nd</sup> edn, IBDC Publishers, Lucknow, India, p. 103.

□