

**AVITELLINA CENTRIPUNCTATA INFECTION IN NILGAI *BOSELAPHUS TRAGOCAMELUS***

B. P. Kamdi, P. M. Kulurkar, N. V. Kurkure, S. W. Kolte, R. Pande, S. W. Raut,  
A. G. Bhandarkar, and P. M. Sonkusale

Department of Veterinary Pathology,  
Nagpur Veterinary College, Seminary Hills, Nagpur-440006, Maharashtra.

Received 23-9-2014 Accepted 2-8-2014

Corresponding Author : bhupeshkamdi@gmail.com

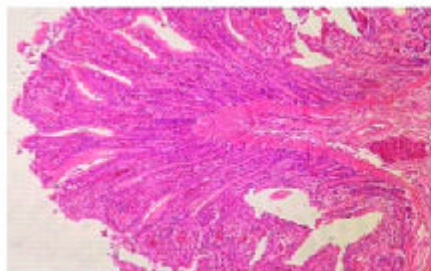
The largest species of antelope Nilgai (*Boselaphus tragocamelus*) is a common wild animal of India and Pakistan. The health condition of the animal is severely affected by various pathogens including parasitic infections. The infection of adult tapeworm parasites in herbivores animals adversely affects the growth, production and immune status of animals. Their systemic study in wild as well as domesticated animals is of upmost importance. Information regarding the prevalence of tape worm infection in Nilgai from Central India is not well documented till date. The present communication deals with the occurrence of tapeworm infection in Nilgai from Central India.

**CASE STUDY**

A carcass of Nilgai from forest department seminary hills Nagpur was brought to the department of Veterinary Pathology for post mortem examination. Detailed post mortem was conducted and systemic necropsy findings revealed sever congestion of small intestine due to presence of the numerous tapeworms. The recovered worms were collected in 70% alcohol for further identification while affected portion of intestine was preserved in 10% buffered formal saline solution for further histopathological examination. Samples were processed by routine procedure to obtain 5 $\mu$  thick sections from paraffin blocks which were stained with the hematoxaline and eosin stain (H & E). Identification of Tape worm was performed based on morphological characters described by Soulsby (1982).

**RESULT AND DISCUSSION**

The collected tapeworms were morphologically identified as *Avitellina centripunctata* belonging to family Anoplocephalidae. Adult worms were 3 to 3.5 m in length and 2.5 to 3 mm in width, posterior end of the worms was cylindrical. Proglottids were short and not distinctly segmented. The uterus was transversed in the middle portion of the proglottid, eggs were present in the par-uterine organ. In the middle portion of the proglottids, uterus and par-uterine organs showed opaque line. Histopathology of affected portion of intestine revealed hemorrhages, congestion with engorgement of sub mucosal vessels, sloughing of epithelial cells from tip of the villi and vacuolar degenerative changes in glandular portion of intestine. Various workers reported the prevalence of *Avitellina centripunctata* in Kashmir valley (Tariq *et al.* ,2008), Egypt (Mohammed, 2008) and in Gambia (Fritsche *et al.* ,1993) .



**Fig. 1** Hemorrhages in intestine



**Fig. 2** Tapeworms recovered from intestine of Nilgai

Tandan *et al.* (2005) studied the cestode (Anoplocephala) infections in the siri cattle of mountainous region of Bhutan and Arunachal Pradesh.

**REFERENCES :**

Mohammed, O. A. S. (2008). Helminth parasites of sheep and goats, a Master of Veterinary Medical Science thesis submitted to Zagazig University, Parasitology department, Egypt.

Fritsche, T., Kaufmann, J. and Pfister, K. (1993). *Vet. Parasitol.* 49 (2-4): 271-283.

Soulsby, E. J. L. (1982). *Helminth, arthropods and protozoa of domesticated animals*, 7th ed. ELBS, London, U.K.

Tandon, V., Kar, P. K., Das, B., Sharma, B. and Dorjee, J. (2005). *Zoos Print J.* 20(5):1867-68.

Tariq, K. A., Chishti, M. Z. and Ahmad, F. (2008) *J. Parasitic Dis.* 32(1): 60-63

□